

Images in clinical medicine



Nasal sarcoidosis

 **Fadwa Mekouar, Mohamed Elqatni**

Corresponding author: Fadwa Mekouar, Internal Medicine B, Mohammed V Military Teaching Hospital, Sidi Mohamed Ben Abdellah University, Fes, Morocco. fadmek2000@hotmail.com

Received: 17 Oct 2021 - **Accepted:** 26 Oct 2021 - **Published:** 03 Nov 2021

Keywords: Sarcoidosis, granulomatous disease, diagnosis

Copyright: Fadwa Mekouar et al. Pan African Medical Journal (ISSN: 1937-8688). This is an Open Access article distributed under the terms of the Creative Commons Attribution International 4.0 License (<https://creativecommons.org/licenses/by/4.0/>), which permits unrestricted use, distribution, and reproduction in any medium, provided the original work is properly cited.

Cite this article: Fadwa Mekouar et al. Nasal sarcoidosis. Pan African Medical Journal. 2021;40(134). 10.11604/pamj.2021.40.134.32076

Available online at: <https://www.panafrican-med-journal.com//content/article/40/134/full>

Nasal sarcoidosis

Fadwa Mekouar^{1,&}, Mohamed Elqatni¹

¹Internal Medicine B, Mohammed V Military Teaching Hospital, Sidi Mohamed Ben Abdellah University, Fes, Morocco

&Corresponding author

Fadwa Mekouar, Internal Medicine B, Mohammed V Military Teaching Hospital, Sidi Mohamed Ben Abdellah University, Fes, Morocco

Image in medicine

A 19-year-old woman with a two years history of dragging oto-rhino-laryngeal infections, purulent rhinorrhea and sinusitis, polyarthralgia, and an episode of granulomatous uveitis. Clinical examination showed destruction of nasal wing, hepatomegaly and splenomegaly. A rounded lesion with atrophic center in the forearm. Laboratory tests revealed upper limit calcemia, the angiotensin-converting enzyme was high 323 UI/L. Nasal biopsy revealed non-caseating epithelioid-cell granulomas. Differential diagnosis includes granulomatous disease of the nose such as leprosy, tuberculosis and Wegener's granulomatosis. Special staining for typical mycobacterium and

lepra bacilli were negative. The polymerase chain reaction for mycobacterium tuberculosis was negative. There was no renal involvement and the cytoplasmic antineutrophil cytoplasmic antibody

(cANCA/PR3/ANCA) was negative. The diagnosis of nasal sarcoidosis was retained. The patient was treated with prednisone and azathioprine with favorable outcome.

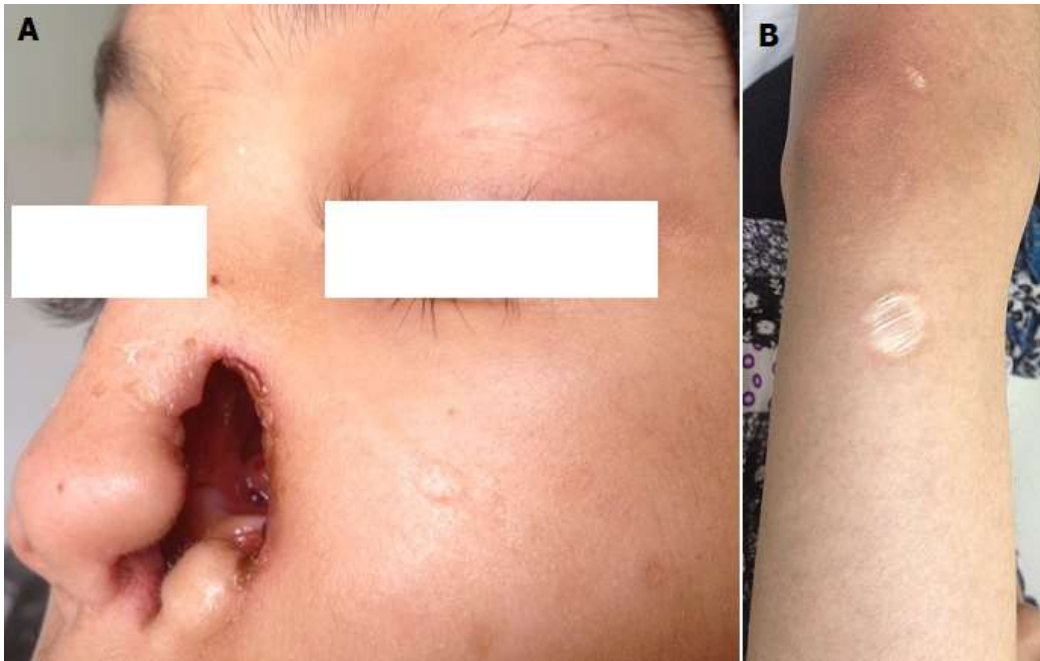


Figure 1:A) destruction of nasal wing, B) rounded lesion with atrophic center in the forearm