

Images in medicine

A closer look at the eyelashes!

Kawtar Belkhadir^{1,2,&}, Ouafae Cherkaoui^{1,2}

¹Mohammed V University, Rabat, Morocco, ²Hôpital des Spécialités, Ophthalmology Department A, Rabat, Morocco

[&]Corresponding author: Kawtar Belkhadir, Mohammed V University, Rabat, Morocco

Key words: Blepharitis, phtirius pubis, infectiology

Received: 22/01/2019 - Accepted: 18/08/2019 - Published: 20/08/2019

Pan African Medical Journal. 2019;33:308. doi:10.11604/pamj.2019.33.308.18232

This article is available online at: <http://www.panafrican-med-journal.com/content/article/33/308/full/>

© Kawtar Belkhadir et al. The Pan African Medical Journal - ISSN 1937-8688. This is an Open Access article distributed under the terms of the Creative Commons Attribution License (<http://creativecommons.org/licenses/by/2.0>), which permits unrestricted use, distribution, and reproduction in any medium, provided the original work is properly cited.

Image in medicine

A 7-year-old child presented with bilateral anterior blepharitis. He had no medical history. The careful examination of the eyelashes found several lice attached to them with their ovoid nits. The parasitological examination revealed a phtirius pubis. Screening of other family members did not find similar effects. The treatment consisted in the removal of all the lesions and their nits. Because mercury-based ointments were unavailable in our country, we have advocated rigorous hygiene of the eyelids, and the use of antibiotic ointment to smother the lice and their nits. The mode of transmission in this case is unknown. There was no evidence of ill-treatment or poor hygiene in the family. The evolution after treatment has been favorable.

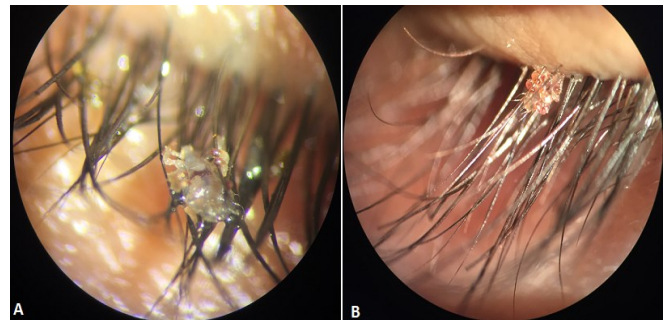


Figure 1: A) phtirius pubis glued to the eyelashes (magnification 40); B) phtirius pubis glued to the eyelashes (magnification 25)