



Images in medicine

Syringomyelia associated to rheumatoid-atlantoaxial subluxation: about a new case

Dhia Kaffel^{1,&}, Wafa Hamdi¹

¹Rheumatology Department, Kassab Institute, Manouba, Tunisia

[&]Corresponding author: Dhia Kaffel, Rheumatology Department, Kassab Institute, Manouba, Tunisia

Key words: Syringomyelia, atlantoaxial subluxation, rheumatoid arthritis

Received: 19/07/2017 - Accepted: 06/10/2017 - Published: 19/10/2017

Pan African Medical Journal. 2017; 28:158 doi:10.11604/pamj.2017.28.158.13403

This article is available online at: <http://www.panafrican-med-journal.com/content/article/28/158/full/>

© Dhia Kaffel et al. The Pan African Medical Journal - ISSN 1937-8688. This is an Open Access article distributed under the terms of the Creative Commons Attribution License (<http://creativecommons.org/licenses/by/2.0>), which permits unrestricted use, distribution, and reproduction in any medium, provided the original work is properly cited.

Image in medicine

We report a case of 64-year-old Tunisian woman with a 12-year history of rheumatoid arthritis, who presented with a 3-month history of increasing inflammatory neck pain. Neurological examination noted a quadripyramidal syndrome without any neurological deficit. Radiographs of her neck showed an anterior atlantoaxial subluxation (A). MRI revealed a pannus around the atlanto axial joint. It also showed a co-existing syringomyelia (B). The cervical spine is frequently involved in patients with rheumatoid arthritis. However, rheumatoid atlantoaxial subluxation with syringomyelia is very rare. Many hypothesised mechanisms were suggested for the syrinx formation. The most commonly admitted, suggested that atlanto axial subluxation may reduce the rate of ascending cerebrospinal fluid, so it would travel through the spinal cord producing syringomyelia.

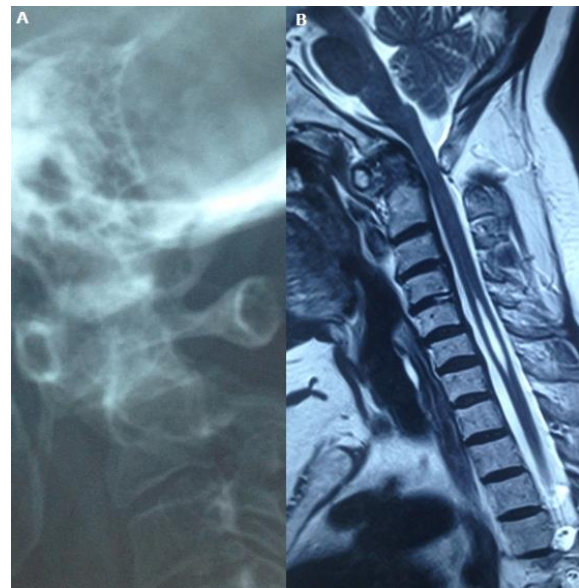


Figure 1: (A) radiograph of a cervical spine showing an anterior atlantoaxial subluxation; (B) MRI showing a pannus around the atlantoaxial joint with a co-existing syringomyelia