

## Research

### Long-term results of retromuscular hernia repair: a single center experience



Ilker Murat Arer<sup>1,&</sup>, Hakan Yabanoglu<sup>1</sup>, Huseyin Ozgur Aytac<sup>1</sup>, Ali Ezer<sup>1</sup>, Kenan Caliskan<sup>1</sup>

<sup>1</sup>Baskent University Adana Teaching and Research Center, Department of General Surgery, Adana, Turkey

<sup>&</sup>Corresponding author: Ilker Murat Arer, Baskent University Adana Teaching and Research Center, Department of General Surgery, Adana, Turkey

Key words: Fascial closure, incisional hernia, mesh repair, retromuscular repair

Received: 18/03/2016 - Accepted: 14/06/2017 - Published: 20/06/2017

#### Abstract

**Introduction:** Incisional hernia (IH) is one of the most frequent postoperative complications after abdominal surgery. There are multiple surgical techniques described for IH repair. The aim of the study is to evaluate the effect of primary fascial closure on long-term results in retromuscular hernia repair (RHR) for incisional hernias. **Methods:** A total of 132 patients underwent RHR for IH were included in our study. 109 patients were evaluated in 2009 and 55 patients in 2015 for short and long-term results. **Results:** Among 132 patients performed RHR, fascia was closed in 107 (81%) and left open in 25 (19%) patients. The mean age of patients was  $57.9 \pm 11.8$  years. Average mesh area was  $439.8 \pm 194.6$  cm<sup>2</sup>, hernia area was  $112 \pm 77.5$  cm<sup>2</sup> and open area after repair was  $40.8 \pm 43.3$  cm<sup>2</sup>. Mean follow-up of 104 patients regarding postoperative complications evaluated in 2009 was  $30.7 \pm 14.1$  months. Recurrent IH was observed in 6 (4.5%) patients according to data collected in 2009. Long-term results were; mean follow-up period was  $91 \pm 20.2$  months (20-112 months) and recurrent IH was observed in 4 (7.3%) patients. **Conclusion:** Retromuscular repair for incisional hernia regardless of the fascial closure gives high patient satisfaction, less recurrence rates and complications in long-term follow-up.

**Pan African Medical Journal. 2017;27:132. doi:10.11604/pamj.2017.27.132.9367**

This article is available online at: <http://www.panafrican-med-journal.com/content/article/27/132/full/>

© Ilker Murat Arer et al. The Pan African Medical Journal - ISSN 1937-8688. This is an Open Access article distributed under the terms of the Creative Commons Attribution License (<http://creativecommons.org/licenses/by/2.0>), which permits unrestricted use, distribution, and reproduction in any medium, provided the original work is properly cited.

## Introduction

---

Incisional hernia (IH) is one of the most common postoperative complication after abdominal operations, with an incidence between 11-20% [1,2]. In high-risk patients such as aortic surgery, this incidence can rise over 35% [3-5]. IH can result in complications such as gastrointestinal obstruction and enterocutaneous fistula [6,7]. Thus rapid diagnosis and treatment is mandatory for undesirable consequences. There are multiple surgical techniques described in literature. By the invention of prosthetic mesh, there is a trend towards the mesh use for IH. The prosthetic mesh leads improvement in long-term results but the location of the mesh is crucial and it is found to be associated with a high incidence of complications, such as surgical site infection, seroma or gastrointestinal fistula [6,8,9]. Positioning of the mesh can be onlay, sublay and inlay. In Chevrel or onlay repair, after dissecting the subcutaneous tissue and approximating 2 edges of the fascia, mesh is placed on the anterior rectus sheath [10]. This can be performed when the two edges of the fascia can be approximated. But for larger defects this approximation can be impossible or yield increased tension on the fascia leading to recurrence. There comes in mind another technique described by Ramirez et al. [11], component separation technique, composed of bilateral release of the external abdominal oblique muscle and fascia, that aids moving the rectus muscles towards the midline to prevent excessive tension. However, component separation found to be inappropriate for fascial defects >15 cm regarding high recurrence rates [12-14]. There is another alternative technique for component separation which is described by Rives-Stoppa, sublay repair technique, in which the mesh is placed on the posterior rectus sheath [15]. In a recent meta-analysis, sublay mesh repair is the recommended technique for IH [16]. The retromuscular hernia repair (RHR), the subject of this article, was first described in 1973 [17]. Flament et al. [18] considered this technique as the "gold standard" for midline incisional hernias with a recurrence rate of 6.7 %. Another question for IH repair during RHR was necessity for closure of linea alba. Therefore the aim of this study is to evaluate the effect of primary fascial closure on long-term results in RHR for incisional hernias.

## Methods

---

A total of 132 patients underwent RHR for IH between 2003 and 2009 in Baskent University Adana Teaching and Research center

were included in our study. This study is designated as retrospective analysis of a former prospective study to collect the long-term results of IH repair. The data were collected prospectively. Of 132 patients 28 were excluded due to failure to reach the patients. Of 104 patients evaluated in 2009 for early postoperative complications, 82 (78.84%) were evaluated by a questionnaire form applied via telephone and 22 (21.16%) by physical examination (Figure 1). In 2015 a total of 55 patients were reached via telephone, to collect the data of long-term postoperative complications (Figure 2). Verbal informed consent was taken from all patients. In one group the anterior rectus sheath was closed using continuous 1/0 polypropylene sutures (Figure 3), in other group sheath was sutured to the polypropylene mesh where they lay (Figure 4). Statistical analysis was performed with the statistical package SPSS software (Version 17.0, SPSS Inc., Chicago, IL, USA). If continuous variables were normal, they were describe as the mean±standard deviation ( $p>0.05$  in Kolmogorov-Smirnov test or Shapiro-Wilk ( $n<30$ )), and if the continuous variables were not normal, they were described as the median. Comparisons between groups were applied using Student T test for normally distributed data and Mann Whitney U test were used for the data not normally distributed. Values of  $p < 0.05$  were considered statistically.

## Results

---

Among 132 patients were performed RHR, fascia was closed in 107 (81%) and left open in 25 (19%) patients. 85 (64.3%) were female and 47 (35.7%) were male. The mean age of patients was  $57.9 \pm 11.8$  years (range between 27-82 years). Characteristics of all 132 patients are described on Table 1. The mean body mass index (BMI) was  $30.6 \pm 5.7$  kg/cm<sup>2</sup>. Average mesh area was  $439.8 \pm 194.6$  cm<sup>2</sup>, hernia area was  $112 \pm 77.5$  cm<sup>2</sup> and open area after repair was  $40.8 \pm 43.3$  cm<sup>2</sup>. 47 (35.6%) patients have co-morbid disease such as; atherosclerosis (13.6%), chronic obstructive pulmonary disease (9.8%), Diabetes Mellitus (8.3%), cancer (3%), hypertension (2.3%) and chronic renal failure (1.5%). 33 (25%) patients had a history of incisional hernia repair. 21 (15.9%) patients had additional operations such as; adhesiolysis (6 patients), cholecystectomy (5 patients), small bowel resection (4 patients), colon resection (2 patients), hiatal hernia repair (2 patients), appendectomy (1 patient), adrenalectomy (1 patient), cholecystoduodenostomy (1 patient) and primary repair of small bowel (1 patient). Mean hospital stay was 4.2 days (min. 1- max. 14

days). Of 132 patients 24 (18.8%) had early postoperative complications. These are; surgical site infection (8 patients), seroma (8 patients), ileus (4 patients), hematoma (3 patients) and suture reaction (1 patient). Mean follow-up of 104 patients regarding postoperative complications evaluated in 2009 was  $30.7 \pm 14.1$  months. Recurrent IH was observed in 6 (4.5%) patients according to data collected in 2009. Among 55 (41.6%) patients evaluated for long-term follow-up, questionnaire applied via telephone in 2015, 17 (30.9%) were male and 38 (69.1%) were female. Mean age was  $64.3 \pm 11.6$  years (range between 36-89 years). Mean follow-up period was  $91 \pm 20.2$  months (20-112 months) and recurrent IH was observed in 4 (7.3%) patients. Verbal questionnaire yield that; 4 (7.3%) patients feel "very pleased", 42 (76.4%) patients feel "pleased" and 5 (9.1%) patients feel "unhappy". Effect of fascial closure on complication has been investigated in univariate analysis and found to be not statistically significant ( $p=0.441$ ). BMI has been investigated as a risk factor for fascial closure and found to have no effect on fascial closure ( $p=0.421$ ). Hernia area found to be a risk factor for fascial closure ( $p=0.002$ ) however it has no effect on early postoperative recurrency.

## Discussion

---

Incisional hernias are commonly encountered complications after abdominal operations. They have major complications like intestinal obstruction or enteric fistulas. IH are found to be associated with patient factors such as age, obesity, diabetes and surgical factors such as poor surgical technique and wound infection [19]. Despite advances in surgical techniques IH still have incidence of 11-20% after abdominal operations [1,2]. The use of prosthetic mesh can be named as a "milestone" in IH repair. If we consider repair techniques before the milestone, the recurrence rates were found to be as high as 31-49 % [20]. Therefore nearly half of the patients with IH repaired primarily have recurrent hernia. Burger et al. [21] found mesh repair superior to suture repair and states that suture repair for IH should be abandoned. The foreign body and fibrosis effect of the mesh lead to decrease in recurrent hernias. As this foreign body has unique advantages, it also possess some disadvantages like wound infection reported between 4-18 % [20]. Since a variety of mesh have been introduced, surgical techniques have also been changed and designated according to placement of the mesh. Onlay, inlay and sublay placement of the mesh have been reported. However onlay repair is believed to easily performed and

have less operation time, recently there is a trend towards sublay placement regarding lower recurrence rates [9,16]. The intra-abdominal pressure may cause fixation of mesh between the posterior fascia and the abdominal muscle and cause reduction in recurrence rates. In a recent review containing 3,945 large incisional hernia repairs with a diameter of 10 cm or a surface of 100 cm<sup>2</sup> or more, the use of mesh has better recurrence rates and less hazards and sublay positioning of the mesh is also advised [22]. IH in our study can be classified as large incisional hernias with an average surface of  $112 \pm 77.5$  cm<sup>2</sup>. After the introduction of retromuscular hernia repair by Rives and Stoppa et al. [15] this technique became popular and widely performed by surgeons. By creating a potential space back to rectus muscle, a well-vascularised pocket for mesh can be achieved. Conze et al. [23] found recurrences with RHR technique typically occur at the upper border and a sublay placement of mesh with an overlap of more than 5 cm to the edges should be performed. Several prosthesis can be used; polypropylene, polyester based and polytetrafluoroethylene mesh. Search for the optimal prosthetic material lead authors to compare light and heavy-weight meshes. However no consensus has been achieved yet.

Introduction of dual mesh that can be placed intraperitoneally, encouraged surgeons to perform laparoscopic repair which yields less scar. Navara et al. [24] compared RHR and laparoscopic incisional hernia repair on 24 patients and found laparoscopic repair safe and feasible but large scaled studies and long-term follow-up should be done. Petro et al. [25] found RHR to be advantageous for the prediction of surgical site occurrence. Surgical site infection rates of 0.6 % in the current study is far below literature results unless recurrent IH was observed in 7.3% patients. This paradox suggests us to investigate closure of fascia as a risk factor in development of recurrent disease. Cobb et al. [26] searched for this issue and found fascial closure had no impact on recurrence, surgical site infection and surgical site occurrence. We also found leaving fascia open or closed has no impact on recurrence or complications. Long-term follow-up of IH repair (average 97 months for both) similar to average of our study (average 91 months) are evaluated by several studies [27,28]. However the mesh was placed intraperitoneally in them. In order to evaluate recurrence rates long-term follow-up should be performed. The study of Kruzer et al. [29] has a median follow-up of 84 months near to our study. They also performed sublay repair. Long-term patient satisfaction has been evaluated by few studies. Postoperative discomfort has an incidence of 14-45 % however Kruzer et al. [29] found this ratio to be 6 %. Our findings

of patients feeling pleased was 76.4 % that is above Kruger's findings that was 49 %.

## Conclusion

---

Incisional hernia repair can be performed by several techniques according to mesh positioning. Retromuscular repair for incisional hernia regardless of the fascial closure gives high patient satisfaction and less recurrence rates and complications in long-term follow-up.

### What is known about this topic

- The retromuscular repair for incisional hernia is the gold standard with a recurrence rate of 6.7 %;
- The effect of fascial closure in retromuscular repair is still debate;
- Long-term results of retromuscular repair is evaluated by a few studies.

### What this study adds

- Fascial closure has no effect on recurrence or patient satisfaction;
- In long-term follow-up retromuscular repair has a recurrence rate of 7.3 %;
- Patient satisfaction rates are high for retromuscular repair.

## Competing interests

---

The authors declare no competing interest.

## Authors' contributions

---

Design and concept of study has made by Ilker Murat Arer, Ali Ezer and Kenan Caliskan. Acquisition of data by Hakan Yabanoglu, Huseyin Ozgur Aytac. Data analysis and interpretation by Ilker Murat Arer, Hakan Yabanoglu, Huseyin Ozgur Aytac. Manuscript draft by Ilker Murat Arer, Hakan Yabanoglu, Huseyin Ozgur Aytac. Statistical expertise by Ali Ezer, Kenan Caliskan. Administrative by

Ali Ezer, Kenan Caliskan. All the authors have read and agreed to the final manuscript.

## Acknowledgments

---

This study did not receive any specific funding or grants.

## Table and figures

---

**Table 1:** Characteristics of patients in both groups

**Figure 1:** Scheme describing evaluation of patients in 2009 and 2015

**Figure 2:** Scheme describing satisfaction level of patients for incisional hernia repair

**Figure 3:** Retromuscular hernia repair with closure of anterior rectus sheath

**Figure 4:** Retromuscular hernia repair without closure of anterior rectus sheath

## References

---

1. Mudge M, Hughes LE. Incisional hernia: a 10 year prospective study of incidence and attitudes. *Br J Surg.* 1985;72(1):70-71. [PubMed](#) | [Google Scholar](#)
2. Hoer J, Lawong G, Klinge U, Schumpelick V. Factors influencing the development of incisional hernia: a retrospective study of 2,983 laparotomy patients over a period of 10 years. *Chirurg.* 2002;73(5):474-480. [PubMed](#) | [Google Scholar](#)
3. Adye B, Luna G. Incidence of abdominal wall hernia in aortic surgery. *Am J Surg.* 1998;175(5):400-402. [PubMed](#) | [Google Scholar](#)
4. Stevick CA, Long JB, Jamasbi B, Nash M. Ventral hernia following abdominal aortic reconstruction. *Am Surg.* 1988;54(5):287-289. [PubMed](#) | [Google Scholar](#)

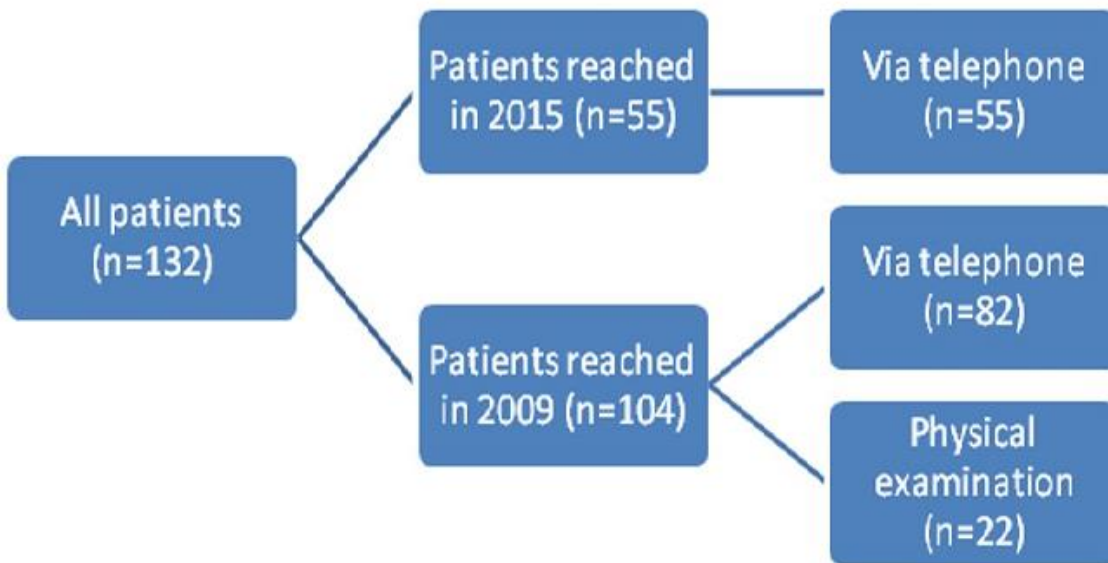
5. Bevis PM, Windhaber RA, Lear PA, Poskitt KR, Earnshaw JJ, Mitchell DC. Randomized clinical trial of mesh versus sutured wound closure after open abdominal aortic aneurysm surgery. *Br J Surg.* 2010;97(10):1497-1502. **PubMed | Google Scholar**
6. Cassar K, Munro A. Surgical treatment of incisional hernia. *Br J Surg.* 2002;89(5):534-545. **PubMed | Google Scholar**
7. Den Hartog D, Dur AH, Tuinebreijer WE, Kreis RW. Open surgical procedures for incisional hernias. *Cochrane Database Syst Rev.* 2008;(3):CD006438. **PubMed | Google Scholar**
8. Luijendijk RW, Hop WC, van den Tol MP, de Lange DC, Braaksma MM, IJzermans JN et al. A comparison of suture repair with mesh repair for incisional hernia. *N Engl J Med.* 2000;343(6):392-398. **PubMed | Google Scholar**
9. De Vries Reilingh TS, van Geldere D, Langenhorst B, de Jong D, van der Wilt GJ, van Goor H et al. Repair of large midline incisional hernias with polypropylene mesh: comparison of three operative techniques. *Hernia.* 2004;8(1):56-59. **PubMed | Google Scholar**
10. Chevrel JP. The treatment of large midline incisional hernias by "overcoat" plasty and prothesis (author's transl). *Nouv Presse Med.* 1979;8(9):695-696. **PubMed | Google Scholar**
11. Ramirez OM, Ruas E, Dellon AL. "Components separation" method for closure of abdominal-wall defects: an anatomic and clinical study. *Plast Reconstr Surg.* 1990;86(3):519-526. **PubMed | Google Scholar**
12. Sukkar SM, Dumanian GA, Szczerba SM, Tellez MG. Challenging abdominal wall defects. *Am J Surg.* 2001;181(2):115-121. **PubMed | Google Scholar**
13. Ko JH, Wang EC, Salvay DM, Paul BC, Dumanian GA. Abdominal wall reconstruction: lessons learned from 200 "components separation" procedures. *Arch Surg.* 2009;144(11):1047-1055. **PubMed | Google Scholar**
14. DiCocco JM, Magnoli LJ, Emmett KP, Zarzaur BL, Croce MA, Sharpe JP et al. Long-term follow-up of abdominal wall reconstruction after planned ventral hernia: a 15-year experience. *J Am Coll Surg.* 2010;210(5):686-698. **PubMed | Google Scholar**
15. Stoppa RE, Warlaumont CR, Verhaeghe PJ, Romero ER, M'Balla-N'Di CJ. Prosthetic repair in the treatment of groin hernias. *Int Surg.* 1986;71(3):154-158. **PubMed | Google Scholar**
16. Timmermans L, de Goede B, van Dijk SM, Kleinrensink GJ, Jeekel J, Lange JF. Meta-analysis of sublay versus onlay mesh repair in incisional hernia surgery. *Am J Surg.* 2014;207(6):980-988. **PubMed | Google Scholar**
17. Rives J, Lardennois B, Pire JC, Hibon J. Large incisional hernias: the importance of flail abdomen and of subsequent respiratory disorders. *Chirurgie.* 1973;99(8):547-563. **PubMed | Google Scholar**
18. Flament JB. Retro rectus approach to ventral hernia repair. *Operative Techniques in General Surgery.* 2004;6(3):165-178. **PubMed | Google Scholar**
19. Bucknall TE, Cox PJ, Ellis H. Burst abdomen and incisional hernia: a prospective study of 1129 major laparotomies. *Br Med J(Clin Res Ed).* 1982;284(6320):931-933. **PubMed | Google Scholar**
20. Cassar K, Munro A. Surgical treatment of incisional hernia. *Br J Surg.* 2002;89(5):534-545. **PubMed | Google Scholar**
21. Burger JW, Luijendijk RW, Hop WC, Halm JA, Verdaasdonk EG, Jeekel J. Long-term follow-up of a randomized controlled trial of suture versus mesh repair of incisional hernia. *Ann Surg.* 2004;240(4):578-83( discussion 583-585). **PubMed | Google Scholar**
22. Deerenberg EB, Timmermans L, Hogerzeil DP, Slieker JC, Eilers PH, Jeekel J et al. A systematic review of the surgical treatment of large incisional hernia. *Hernia.* 2015;19(1):89-101. **PubMed | Google Scholar**

23. Conze J, Prescher A, Klinge U, Saklak M, Schumpelick V. Pitfalls in retromuscular mesh repair for incisional hernia: The importance of the "fatty triangle". *Hernia*. 2004;8(3): 255-259. **PubMed | Google Scholar**
24. Navarra G, Musolino C, De Marco ML, Bartolotta M, Barbera A, Centorrino T. Retromuscular sutured incisional hernia repair: a randomized controlled trial to compare open and laparoscopic approach. *Surg Laparosc Endosc Percutan Tech*. 2007;17(2):86-90. **PubMed | Google Scholar**
25. Petro CC, Posielski NM, Raigani S, Criss CN, Orenstein SB, Novitsky YW. Risk factors for wound morbidity after open retromuscular (sublay) hernia repair. *Surgery*. 2015;158(6):1658-1668. **PubMed | Google Scholar**
26. Cobb WS, Warren JA, Ewing JA, Burnikel A, Merchant M, Carbonell AM. Open retromuscular mesh repair of complex incisional hernia: predictors of wound events and recurrence. *J Am Coll Surg*. 2015;220(4):606-613. **PubMed | Google Scholar**
27. Hamy A, Pessaux P, Mucci-Hennekinne S, Radriamananjo S, Regenat N, Arnaud J-P. Surgical treatment of large incisional hernias by an intraperitoneal dracon mesh and an aponeurotic graft. *J Am Coll Surg*. 2003;196(4):531-534. **PubMed | Google Scholar**
28. Arnaud JP, Tuech JJ, Pessaux P, Hadchity Y. Surgical treatment of postoperative incisional hernias by intraperitoneal insertion of dracon mesh and an aponeurotic graft: a report on 250 cases. *Arch Surg*. 1999;134(11):1260-1262. **PubMed | Google Scholar**
29. Kurzer M, Kark A, Selouk S, Belsham P. Open mesh repair of incisional hernia using a sublay technique: long-term follow-up. *World J Surg*. 2008;32(1):31-36(discussion 37). **PubMed | Google Scholar**

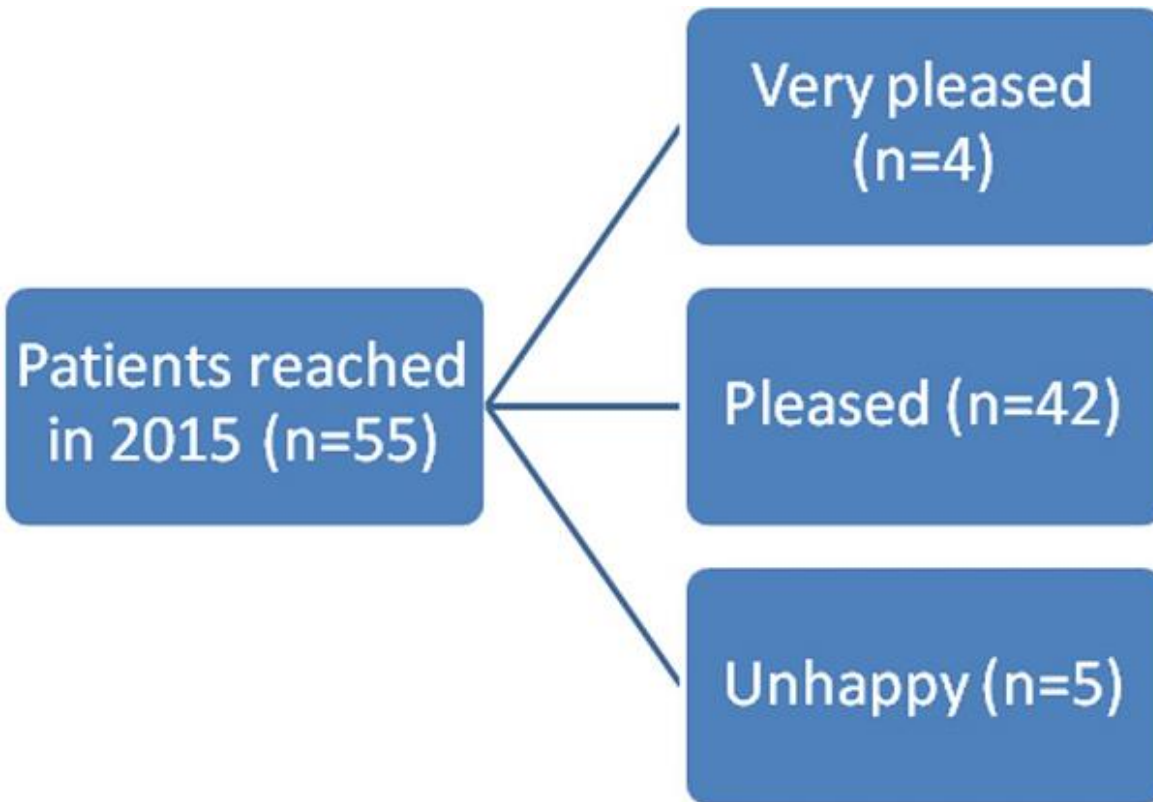
**Table 1:** Characteristics of patients in both groups

	<b>Number of patients</b>	<b>Minimum</b>	<b>Maximum</b>	<b>Mean<sup>+</sup></b>
Age	132	27	82	57.9±11.8
BMI (kg/cm <sup>2</sup> )	132	17.5	54	30.6±5.7
Hernia area (cm <sup>2</sup> )	132	15.7	353.2	112±77.5
Mesh area (cm <sup>2</sup> )	132	100	900	439.8±194.6
Open area (cm <sup>2</sup> )	25	5	169.5	40.8±43.3
Hospital stay (Days)	132	1	14	4.2±1.9
Follow-up in 2009 (Months)	104	12	71	30.7±14.1
Follow-up in 2015 (Months)	55	20	112	91±20.2

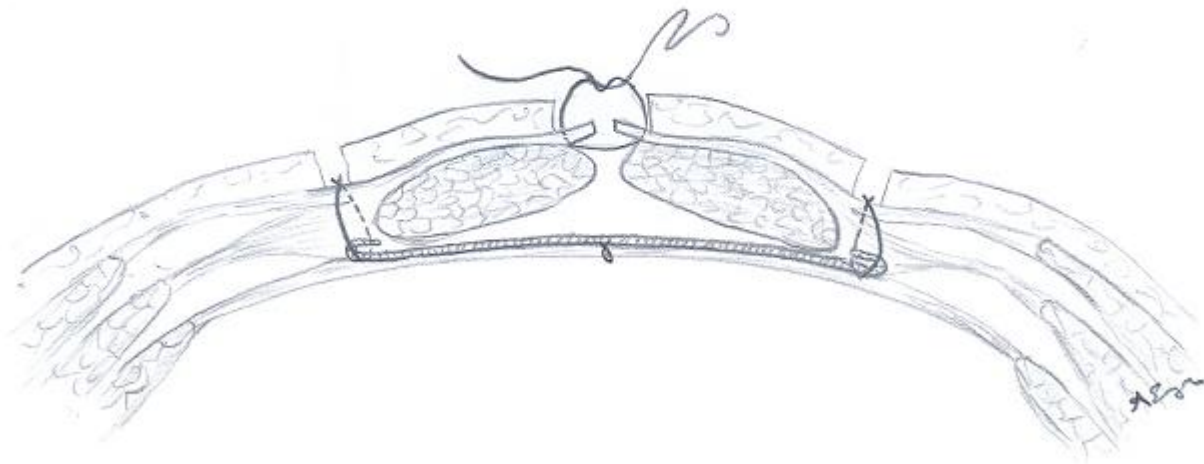
Abbreviations: BMI; Body mass index. <sup>+</sup>Values are means±standard deviation



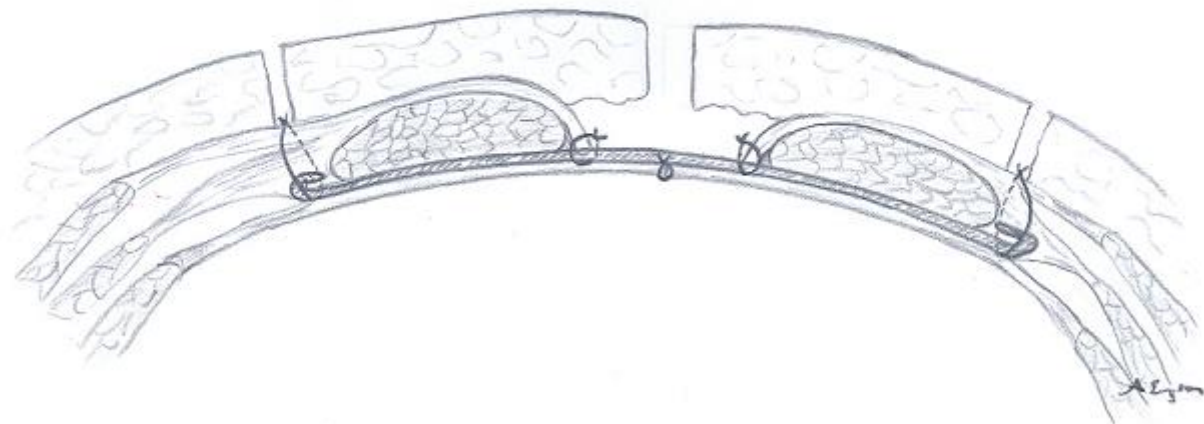
**Figure 1:** Scheme describing evaluation of patients in 2009 and 2015



**Figure 2:** Scheme describing satisfaction level of patients for incisional hernia repair



**Figure 3:** Retromuscular hernia repair with closure of anterior rectus sheath



**Figure 4:** Retromuscular hernia repair without closure of anterior rectus sheath