

Images in medicine

Lombosciatique révélant un épendymome intramédullaire



Lumbosciatica revealing intramedullary ependymoma

Zeineb Alaya^{1&}, Walid Osman²

¹Service de Rhumatologie, Hôpital Farhat Hached, Sousse, Tunisie, ²Service d'Orthopédie, Hôpital Sahloul, Sousse, Tunisie

[&]Corresponding author: Zeineb Alaya, Service de Rhumatologie, Hôpital Farhat Hached, avenue Ibn El Jazzar, 4000, Sousse, Tunisie

Mots clés: Lombosciatique, IRM, tumeur rachidienne, épendymome

Received: 12/01/2017 - Accepted: 13/03/2017 - Published: 24/03/2017

Pan African Medical Journal. 2017;26:171. doi:10.11604/pamj.2017.26.171.11633

This article is available online at: <http://www.panafrican-med-journal.com/content/article/26/171/full/>

© Zeineb Alaya et al. The Pan African Medical Journal - ISSN 1937-8688. This is an Open Access article distributed under the terms of the Creative Commons Attribution License (<http://creativecommons.org/licenses/by/2.0>), which permits unrestricted use, distribution, and reproduction in any medium, provided the original work is properly cited.

Image en médecine

A 68-year-old patient presented with bilateral inflammatory lumbosciatic pain evolving since four months with no vesico-sphincteric disorders and no associated general signs. The examination showed that the patient moves with small steps with anteflexion of the trunk. The patient had disappearance of lumbar lordosis, lumbar spine stiffness, and bilateral positive sign of Lasegue, sharp osteo-tendinous reflexes to the lower limbs with no sensory-motor deficit or saddle anesthesia. The biological assessment did not show any inflammatory syndrome. Radiographs of the lumbar spine were normal. Faced with the atypical nature of the clinical picture, a spinal MRI was performed showing the intraductal presence of an oval formation behind the vertebral body of L4, measuring 3 cm in height which appears in discrete hypersignal T1 (A) and hypersignal T2 (B) enhanced after injection of gadolinium and comprising a superior polar cystic component. The patient had a tumor excision in orthopaedics. Histological examination of the surgical specimen led to myxopapillary ependymoma.

Key words: *Lumbosciatica pain, MRI, spinal tumor, ependymoma*

We here report the case of a 68-year old female patient presenting with inflammatory poorly systematized bilateral lumbosciatica, without vesico-sphincteric disorders or associated general symptoms evolving for 4 months. Physical exam showed gait with little steps with trunk anteflexion, disappearance of lumbar lordosis, lumbar spine stiffness, positive bilateral Lasègue's test and hyperactive osteotendinous reflexes in lower limbs without motor and sensory deficit or saddle block anesthesia. Laboratory tests did not show any inflammatory syndrome. Lumbar spine X-rays were normal. Given the abnormal clinical picture, spinal MRI was performed which showed oval intracanal mass behind L4 vertebral body, measuring 3 cm height with discrete hypersignal on T1 (A) and with hypersignal on T2 (B), enhanced after gadolinium administration and containing superior polar cystic component. The patient underwent tumor resection in orthopaedics. Histological examination of the surgical specimen revealed myxopapillary ependymomas.

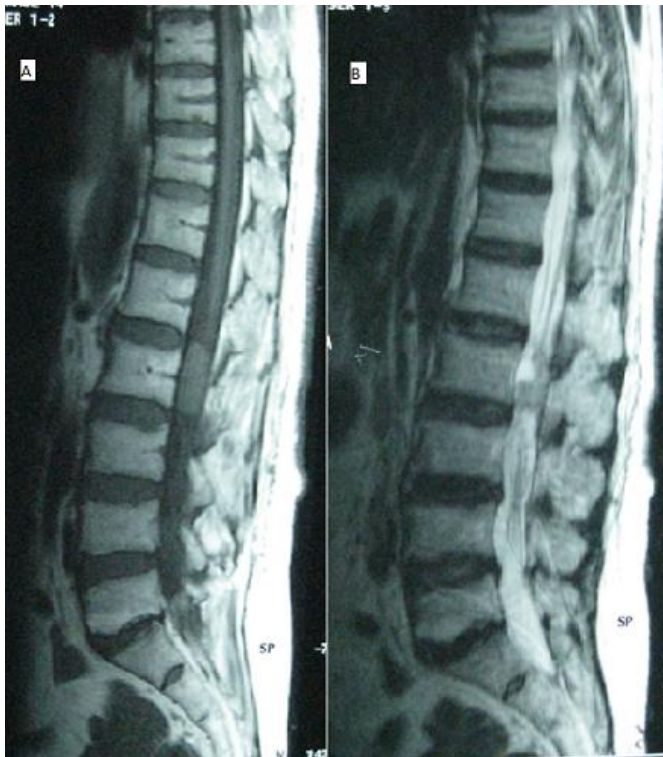


Figure 1: IRM rachidienne: présence en intra-canaulaire d'une formation ovale en arrière du corps vertébral de L4, mesurant 3 cm de hauteur qui apparait en discret hypersignal T1 (A) et en hypersignal T2 (B), se réhaussant après injection de gadolinium et comportant une composante kystique polaire supérieure