

Case report

A pathological fracture of the scaphoid revealing an intraosseous ganglion cyst

Mohamed Ali Sbai^{1, *}, Sofien Benzarti¹, Feten Sbei¹, Riadh Maalla²

¹Orthopedic Surgery and Trauma Department, Maamouri Hospital, Nabeul, Tunisia, ²Plastic Surgery Department, La Rabta Hospital, Tunis, Tunisia

*Corresponding author: Mohamed Ali Sbai, Orthopedic Surgery and Trauma Department, Maamouri Hospital, Nabeul, Tunisia

Key words: Intraosseous, ganglion cyst, pathologic fracture, scaphoid bone, bone grafting, carpal bone, wrist

Received: 14/10/2015 - Accepted: 08/03/2016 - Published: 14/04/2016

Abstract

Intraosseous ganglion cyst is a benign bone lesion with histological similarities to the soft tissue ganglion cyst. Its location on the short bones, including the carpal bones has rarely been reported. The radiolucent carpal lesions are usually symptom-free found incidentally on radiographs of the wrist performed for other reasons. Detecting a pathological fracture of the scaphoid revealing an intraosseous ganglion cyst is exceptional. We report the case of a 21-year-old, right-handed male, presented with a one year history of progressive right-wrist pain, worsened since a month without a history of previous trauma. Plain radiographs and CT-scan revealed a cystic lesion of the scaphoid with a pathological fracture. He was successfully treated with curettage and packing with a Zaidenberg's vascularized radial graft without recurrence at two years postoperatively.

Pan African Medical Journal. 2016; 23:185 doi:10.11604/pamj.2016.23.185.8188

This article is available online at: <http://www.panafrican-med-journal.com/content/article/23/185/full/>

© Mohamed Ali Sbai et al. The Pan African Medical Journal - ISSN 1937-8688. This is an Open Access article distributed under the terms of the Creative Commons Attribution License (<http://creativecommons.org/licenses/by/2.0>), which permits unrestricted use, distribution, and reproduction in any medium, provided the original work is properly cited.

Introduction

Intraosseous ganglion cyst is a benign bone lesion with histological similarities to the soft tissue ganglion cyst. Its location on the short bones, including the carpal bones has rarely been reported. The radiolucent carpal lesions are usually symptom-free found incidentally on radiographs of the wrist performed for other reasons. Detecting a pathological fracture of the scaphoid revealing an intraosseous ganglion cyst is exceptional.

Patient and observation

A 21-year-old, right-handed male, without any pathological history, presented with a one year history of progressive right-wrist pain partially improved after receiving analgic and anti-inflammatory treatment. Symptomatology has worsened since a month without a history of previous trauma. Clinical study revealed a moderate swelling over the palmar aspect of the wrist. Grip strength was decreased and wrist motion was slightly limited and painful at extreme ranges of motion. Plain radiographs of the right wrist revealed a round-shaped radiolucent lesion of the scaphoid with a thin marginal sclerosis and a pathological fracture (Figure 1). CT-scan confirmed a cystic lesion of the scaphoid and was able to localize the lesion and the fracture precisely. Other carpal bones and adjacent joints were normal (Figure 2, Figure 3). The patient was operated using the anterior surgical approach of the scaphoid; both the scaphoid and the distal radius were exposed for harvesting vascularized bone. Through the defect on the volar aspect of the scaphoid, the cystic lesion was curetted out revealing atypical yellowish gelatinous material. The cavity was rinsed using a saline solution, then packed with a Zaidenberg's vascularized radial graft. After closing the joint capsule, the subcutaneous and cutaneous tissues, a removable wrist cast was applied for five weeks. Macroscopic and microscopic findings were characteristics of an intraosseous ganglion cyst (IGC). The patient was successfully treated surgically. The patient was completely relieved from pain with a slight limitation of the wrist motion and full grip strength, 3 months after operation (Figure 4, Figure 5). At the latest follow-up, two years postoperatively, plain radiographs show complete integration of the graft without recurrence (Figure 6, Figure 7).

Discussion

IGC is a benign bone tumor of osteolytic type. It usually develops in the epiphysis and metaphysis of long bones, mainly in the lower limbs. Its location on the short bones, including the carpal bones has rarely been described [1,2]. To our knowledge, only 16 cases of IGC of the scaphoid have been reported in literature, only 3 of them were complicated by a pathological fracture [3]. IGC of carpal bone is often asymptomatic. It is usually fortuitously discovered during a radiographs made for another reason. In other cases, it is the cause of chronic wrist pain triggered by repeated efforts, partially relieved by conventional analgesics. More rarely the diagnosis can be made by a displaced fracture complicating the IGC. This serious complication is usually post-traumatic and can cause irreversible damage. Plain radiographs typically reveal a well-defined osteolytic area outlined by a sclerotic rim. Differential diagnosis at this stage include chondroma, ostéochondroma, osteoid osteoma and preiser disease [4]. Mnif [3] believes that CT-scan is an optional exam. Dumas [4] believes that it is useful for the diagnosis and to choose the surgical technique and approach, but it is also necessary for the assessment of fracture risk. Fracture risk depends on several

morphological characteristics of IGC. Different stages of IGC in the short bones could be described: strictly intraosseous, single cortical infarction and displaced fracture. The cyst may also vary in size to fill the entire medulla. The fracture risk depends on the size of the intramedullary cavity and the size of the cortical defect [4]. Anatomopathological study of the curettage material is necessary to confirm the diagnosis revealing a cystic wall covered with flattened fibroblast cells close to the synovial cells but without true epithelial lining. It is present in a typical yellowish gelatinous liquid [1, 2]. The choice of treatment depends on the clinical and the radiological study. Surgical treatment should be indicated if the IGC is symptomatic or if it is associated with high risk of fracture, to prevent this particular complication and within irreversible damage to the wrist [5]. Treatment of IGC consists in the curettage of the cyst, injection of saline solution and packing the cavity with cancellous bone graft. In our case an anterior approach was preferred and a Zaidenberg's vascularized radial bone grafting was performed.

Conclusion

IGC of carpal bone is usually asymptomatic, fortuitously discovered, but could also be revealed by a pathological fracture with or without previous trauma. It is a serious complication that could cause irreversible damage. CT-scan is useful for the assessment of fracture risk. Curettage and packing with vascularized bone graft provides complete relief of pain with good functional result.

Competing interests

The authors declare no competing interest.

Authors' contributions

All authors have read and agreed to the final version of this manuscript and have equally contributed to its content and to the management of the case.

Figures

Figure 1: Plain radiographs of the right wrist revealed a round-shaped radiolucent lesion of the scaphoid with a thin marginal sclerosis and a pathological fracture

Figure 2: Coronal CT-scan confirmed a cystic lesion of the scaphoid and was able to localize the lesion and the fracture precisely. Other carpal bones and adjacent joints were normal

Figure 3: Transverse CT-scan confirmed a cystic lesion of the scaphoid and was able to localize the lesion and the fracture precisely. Other carpal bones and adjacent joints were normal

Figure 4: The patient was completely relieved from pain with a slight limitation of the wrist motion in flexion, 3 months after operation

Figure 5: The patient was completely relieved from pain with full wrist motion in extension and full grip strength, 3 months after operation

Figure 6: Two years postoperatively, antero-posterior view of the wrist showing complete integration of the graft without recurrence

Figure 7: Two years postoperatively, lateral view of the wrist showing complete integration of the graft without recurrence

References

1. Fisk GR. Bone concavity caused by a ganglion. The Journal of bone and joint surgery British volume. 1949 May; 31B(2): 220. [PubMed](#) | [Google Scholar](#)
2. Crabbe WA. Intra-osseous ganglia of bone. The British journal of surgery. 1966 Jan; 53(1): 15-7. [PubMed](#) | [Google Scholar](#)
3. Mnif H, Koubaa M, Zrig M, Jawahdou R, Sahnoun N, Abid A. Ganglion cyst of the carpal navicular. A case report and review of the literature. Orthopaedics & Traumatology: Surgery & Research. 2010; 96(2): 190-193. [PubMed](#) | [Google Scholar](#)
4. Dumas P, Georgiou C, Chignon-Sicard B, Balaguer T, Lebreton E, Dumontier C. Intra-osseous ganglion cyst of the carpal bones. A review of the literature underlining the importance of systematic computed tomography. Chirurgie de la main. 2013 Feb; 32(1): 3-7. [PubMed](#) | [Google Scholar](#)
5. Yakoubi M, Meziani N, Yahia Cherif M, Zemmouri A, Benbakouche R. Pathological fracture of the carpal scaphoid (intra-osseous synovial cyst). Clinical and therapeutic aspect. Case report. Chir Main. 2009 Feb; 28(1): 37-41. [PubMed](#) | [Google Scholar](#)

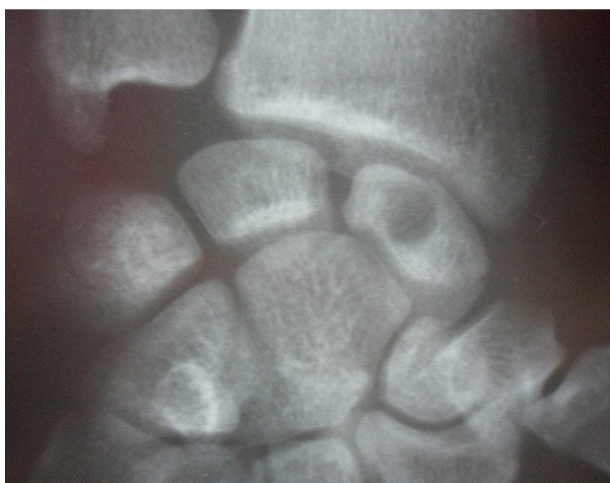

Figure 1: Plain radiographs of the right wrist revealed a round-shaped radiolucent lesion of the scaphoid with a thin marginal sclerosis and a pathological fracture

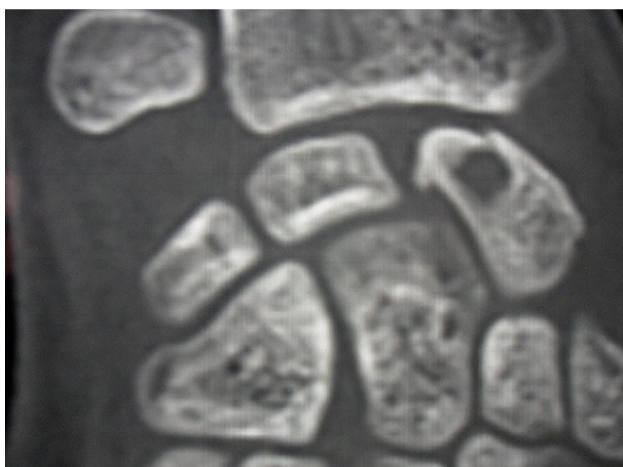


Figure 2: Coronal CT-scan confirmed a cystic lesion of the scaphoid and was able to localize the lesion and the fracture precisely. Other carpal bones and adjacent joints were normal

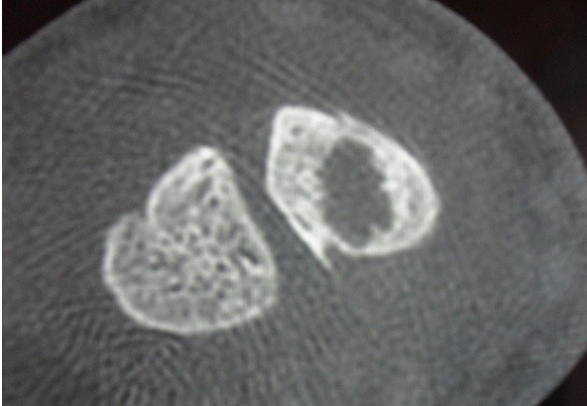


Figure 3: Transverse CT-scan confirmed a cystic lesion of the scaphoid and was able to localize the lesion and the fracture precisely. Other carpal bones and adjacent joints were normal

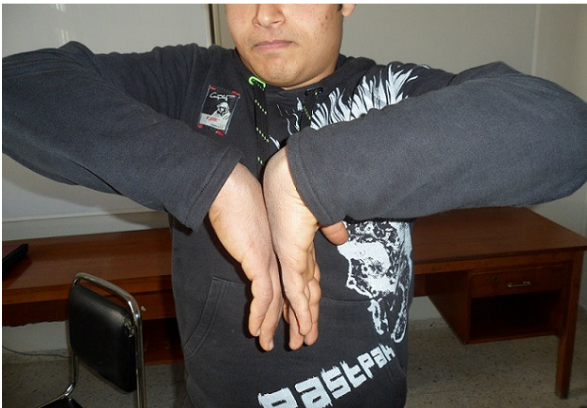


Figure 4: The patient was completely relieved from pain with a slight limitation of the wrist motion in flexion, 3 months after operation



Figure 5: The patient was completely relieved from pain with full wrist motion in extension and full grip strength, 3 months after operation

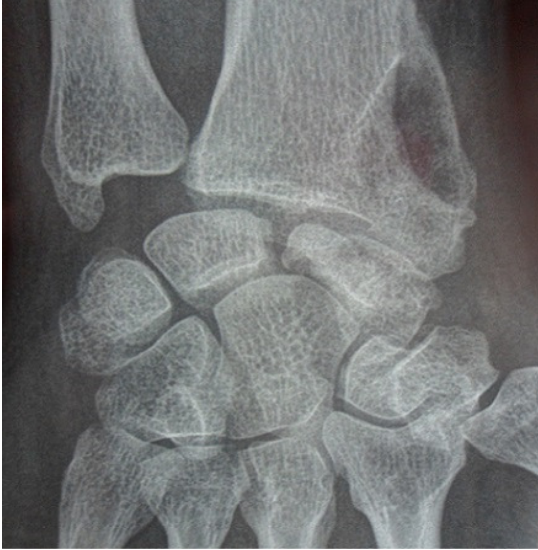

Figure 6: Two years postoperatively, antero-posterior view of the wrist showing complete integration of the graft without recurrence

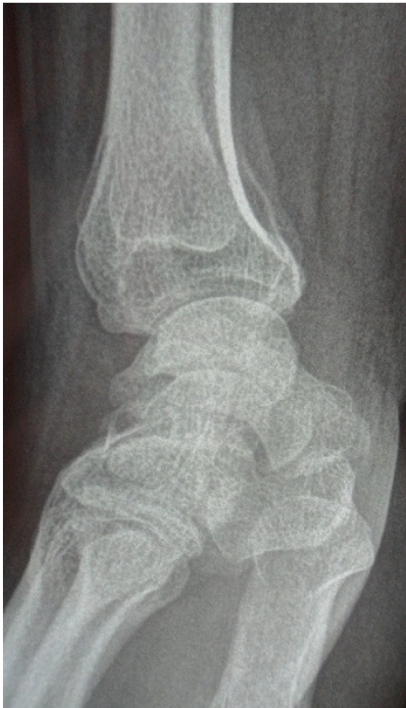

Figure 7: Two years postoperatively, lateral view of the wrist showing complete integration of the graft without recurrence