

Images in medicine

Jugular vein thrombosis due to Behçet disease

Ahmed Belkouch^{1,&}, Lahcen Belyamani¹

¹Emergency Departement, Mohammed V Military Hospital of Instruction, Rabat, Morocco

[&]Corresponding author: Ahmed Belkouch, Emergency Departement, Mohammed V Military Hospital of Instruction, Rabat, Morocco

Key words: Internal jugular vein thrombosis, behçet 's disease, CT angiography

Received: 02/01/2015 - Accepted: 02/03/2015 - Published: 10/03/2015

Pan African Medical Journal. 2015; 20:216 doi:10.11604/pamj.2015.20.216.6060

This article is available online at: <http://www.panafrican-med-journal.com/content/article/20/216/full/>

© Ahmed Belkouch et al. The Pan African Medical Journal - ISSN 1937-8688. This is an Open Access article distributed under the terms of the Creative Commons Attribution License (<http://creativecommons.org/licenses/by/2.0>), which permits unrestricted use, distribution, and reproduction in any medium, provided the original work is properly cited.

Image in medicine

A 46-years-old patient with a 7 years history of oral and genital recurrent ulceration with ocular redness since one year. He was admitted for the management of edema of the face and the neck, the onset was progressive without fever or poor general condition. On physical examination, the patient was aware, he had no fever, heart rate at 80b / min, blood pressure= 14/7, Spo2= 100%. There was no murmur on auscultation of the cervical vessels, and no neurologic deficit. Computed Tomography angiography was performed and revealed an almost complete thrombosis of the right internal jugular vein along 9 cm. the patient received curative dose anticoagulant therapy with good evolution. Behçet's disease is a multisystem disease characterized by a bipolar ulceration, skin lesions, and systemic vasculitis. The prevalence of vascular disease is about 25% and it alone represents the leading cause of death in this condition. Jugular thrombosis is an unusual event. Recent data from the literature support the beneficial effect of anticoagulation

associated with corticosteroids and immunosuppressive therapy in its management.

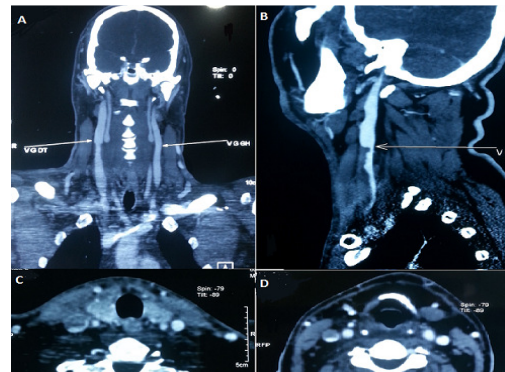


Figure 1: A: CT scan angiography in coronal cut showing the right internal jugular vein thrombosis; B: parasagittal cut showing the thrombosis; C and D: transverse cuts showing the same thrombosis