

Case report

Spontaneous subdural hematoma associated with preeclampsia: a case report and literature review

Nezha Oudghiri^{1,&}, Mehdi Behat¹, Nada Elchhab¹, Mouhssine Doumiri¹, Anas Saoud Tazi¹

¹Department of Obstetrics Intensive Care Unit and Anesthesia, Maternity Souissi Hospital, University Mohamed V, Rabat, Morocco

[&]Corresponding author: Nezha oudghiri, Department of Obstetrics Intensive Care Unit and Anesthesia, Maternity Souissi Hospital, University Mohamed V, Rabat, Morocco

Key words: spontaneous subdural hematoma, pre-eclampsia, neurologic,

Received: 19/09/2014 - Accepted: 21/10/2014 - Published: 28/10/2014

Abstract

A patient with pre-eclampsia at 31 weeks' gestation developed neurologic signs. Computerized tomography revealed a large cranial subdural hematoma. This diagnostic should be considered in any pre-eclamptic patient demonstrating neurological symptoms and must be treated effectively because of the poor maternal and fetal prognosis. Our patient was successfully treated.

Pan African Medical Journal. 2014; 19:213 doi:10.11604/pamj.2014.19.213.5451

This article is available online at: <http://www.panafrican-med-journal.com/content/article/19/213/full/>

© Nezha oudghiri et al. The Pan African Medical Journal - ISSN 1937-8688. This is an Open Access article distributed under the terms of the Creative Commons Attribution License (<http://creativecommons.org/licenses/by/2.0>), which permits unrestricted use, distribution, and reproduction in any medium, provided the original work is properly cited.

Introduction

Intracranial hemorrhage is a rare complication during pregnancy, but potentially fatal, which contributes significantly to maternal mortality. The main causes are ruptured aneurysm, arteriovenous malformations's (MAV) and pregnancy-induced hypertension. The aneurysm or AVM usually causes a subarachnoid hemorrhage; intracranial hemorrhage while associated with pre-eclampsia is usually intra- parenchymal. Subdural hemorrhage associated with pregnancy has been reported in post trauma or as a complication of epidural anesthesia during labor. A spontaneous subdural hematoma associated with preeclampsia, have been reported in some cases in the literature. We now describe such a case.

Patient and observation

A 30-year old primigravid woman with no particular history was hospitalized for management of preeclampsia in pregnancy at 31weeks' gestation. On admission the patient was sleepy with the the glasgow coma scale at 13, eye examination revealed pupils to be equal and reactive to light bilaterally, blood pressure was 150/100 mmHg with 4+proteinuria without signs of trauma, no concept of convulsions, or tongue biting, the patient denied any headache, visual disturbances or epigastric pain. The cardiopulmonary examination was unremarkable. The obstetric examination note long neck and posterior closed and intact membrane. Obstetric ultrasound reveale an estimated fetal age of 27 weeks' with adequate fluid volume. Laboratory studies included a hemoglobin of 13,6g/l, platelet count 178000/mm³, serum glutamic oxaloacetic transaminase (SGOT): 11 IU/L, glutamic puryvate transaminase (SGPT): 15IU/L, urea: 0, 4 g/l, créatinine: 6.6mg/dl, total bilirubin: 8mg/dl. The brain scan objective a subdural hematoma (**Figure 1**). A first dose of betamethasone was administrated to enhance fetal lung maturity. The patient was admitted on the same day in the operating room and the hematoma was evacuated. The evolution was marked by neurological improvement without any motor or sensory deficit; she was well oriented and responsive to questions and commands. At the fifth day the parturient has delivered naturelly a 32 weeks' newborn who died in the ICU because of respiratory distress and prematurity.

Discussion

Intracranial hemorrhage is a rare complication occurring in 0.01-0.05 per cent in pregnancies. The aneurysm or arterio-venous malformations are the most common causes of intracranial hemorrhage. Pregnancy-induced hypertension is also a factor of intra parenchymal hemorrhage [1]. The subdural hematoma is a rare form of intracranial hemorrhage associated with pregnancy. Some cases subdural hematoma resulting from a head injury during pregnancy has been reported [2]. Other cases of subdural hematoma have been reported in post- partum in association with epidural anesthesia [3].

The clinical symptoms described in these patients in post partum presented by: headache, dizziness, disorientation, memory loss, ophthalmoplegia, papilledema, stupor, coma, and psychosis. The onset of these symptoms varies from the first to the fourth day after delivery [3]. It seems clear that it exists an association between trauma, whether related to a direct head injury or secondary to regional anesthesia and the development of a subdural hematoma. An association between pre-eclampsia and spontaneous subdural hematoma has not been previously reported. Gregg Giannina and al described a subdural hematoma during pregnancy in a patient with preeclampsia without notion of trauma. The exact etiology of the hematoma in this patient is not clear. However, thrombocytopenia may have been a predisposing factor for the development of intracranial hemorrhage and / or the inhibition of platelet function due to magnesium sulfate [4]. In our case the patient had a normal count of platelet and did not receive magnesium sulfate before.

Conclusion

The hemorrhagic cerebrovascular accidents during pregnancy are rare, possibly involving maternal and fetal prognosis. They must be detected early and treated effectively, and often requires a multidisciplinary approach.

Competing interests

Authors declare no competing interests.

Authors' contributions

N. Oudghiri is the main corresponding author. All authors participated on the conception, design, acquisition and interpretation of data and declare approving the final version of the manuscript.

Figure

Figure 1: computerized tomography scan of the head demonstrating a midline shift and a large left sided subdural hematoma

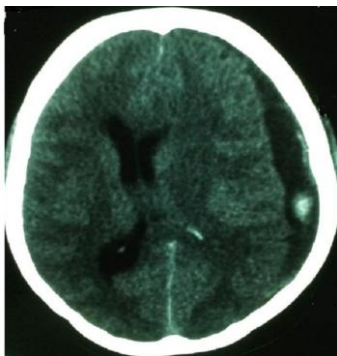


Figure 1: computerized tomography scan of the head demonstrating a midline shift and a large left sided subdural hematoma

References

1. Sharshar T, Lamy C, Mas JL. Incidence and causes of strokes associated with pregnancy and puerperium: A study in public hospitals of Ile de France. Stroke in Pregnancy Study Group. Stroke 1995; June 26(6): 930-936. **PubMed | Google Scholar**
2. Amias AG. Cerebral vascular disease in pregnancy: I Haemorrhage. J Obstet Gynaecol Br Commonw.1970 Feb; 77(2):100-20. **PubMed | Google Scholar**
3. Vaughan DJ, Stirrup CA, Robinson PN. Cranial subdural haematoma associated with dural puncture in labour. British Journal of Anaesthesia. 2000;Apr 84(4): 518-520. **PubMed | Google Scholar**
4. Giannina G, Smith D, Belfort MA, Moise KJ Jr. Atraumatic subdural hematoma associated with pre-eclampsia. J Matern Fetal Med. 1997 Mar-Apr; 6(2): 93-5. **PubMed | Google Scholar**