

## Case report

### **Intraoperative rupture of popliteal artery pseudoaneurysm secondary to distal femur osteochondroma: case report and review of the literature**

**Rita Hajji<sup>1,&</sup>, Hamid Jiber<sup>1</sup>, Youssef Zrihni<sup>1</sup>, Othman Zizi<sup>1</sup>, Abdellatif Bouarroum<sup>1</sup>**

<sup>1</sup>Department of vascular surgery, UHC Hassan II, Fes, Maroc

<sup>&</sup>Corresponding author: Rita Hajji, Department of vascular surgery, UHC Hassan II , Fes, Maroc

Key words: Exostoses, osteochondroma, popliteal artery pseudoaneurysme

Received: 26/10/2013 - Accepted: 03/12/2013 - Published: 20/12/2013

#### **Abstract**

Vascular complications from osteochondroma are rare and include essentially stenosis, occlusion, and pseudoaneurysms. The authors report an original case of intraoperative rupture of undiagnosed popliteal artery pseudoaneurysm during resection surgery for a distal femur osteochondroma.

**Pan African Medical Journal. 2013; 16:150 doi:10.11604/pamj.2013.16.150.3510**

This article is available online at: <http://www.panafrican-med-journal.com/content/article/16/150/full>

© Rita Hajji et al. The Pan African Medical Journal - ISSN 1937-8688. This is an Open Access article distributed under the terms of the Creative Commons Attribution License (<http://creativecommons.org/licenses/by/2.0>), which permits unrestricted use, distribution, and reproduction in any medium, provided the original work is properly cited.

## Introduction

---

Exostoses are the most frequent benign bone tumors. They account from 10 to 15 % of both benign and malignant bone tumors [1,2]. Osteochondroma may be present as a solitary lesion or in exostoses multiple hereditary form. Usually, they are asymptomatic. However, they may cause various complications such as arterial pseudo-aneurysm. This pseudo aneurysm is most often located on the popliteal artery. [3] Pseudo-aneurysm results from an arterial injury due to exostose. Its mechanism development is still unknown because it is usually asymptomatic. Our case involved a 20 year-old boy with multiple hereditary exostoses. A large pseudo-aneurysm was observed and broken during surgery. Then, He was admitted for care in our Hospital. Although arterial pseudo-aneurysms rarely develop, we must always pay attention to patients who present multiple exostoses.

## Patient and observation

---

A 22-year old man with hereditary multiple exostoses was scheduled for a surgical excision of distal right femur osteochondroma. The preoperative evaluation was unremarkable, distal pulses were presents and the leg was well perfused. Knee X-rays showed bilateral distal femoral exostosis (**Figure 1**)

During intervention a massive bleeding occurred, and for hemostasis, the surgeon was forced to lie the popliteal artery. Three hours later, the patient was admitted to our emergency department with a relative ischemia of the right lower limb, with normal vital signs. On physical examination, sensation was present but reduced to the foot, the popliteal and distal pulses were absents. Laboratory tests were normal except for haemoglobin; it was at 9 g/dl. An arteriography was performed and clearly showed a popliteal artery occlusion opposite the incision (**Figure 2**). The patient underwent surgery. The popliteal artery was exposed through a medial supra-geniculate and infrageniculate approach. The artery was found ligated near the prior surgical site. The popliteal artery wall was repaired by veinous graft after vascular clamps were applied (**Figure 3**). The postoperative course was uneventful and the patient regained his normal activity. There was no sign of malignant transformation on histopathological examination of bone

## Discussion

---

Osteochondroma is one of the most common bone tumors. It is exceptionnaly responsible for vascular complications from which pseudo-aneurysm constitutes the most frequent entity. Hereditary multiple exostoses is a multi-phenotypic autosomal dominant disorder that affects 1 per 50000 in the general population for Caucasians [4]. It is a disorder mapped to the exostoses genes (EXT) [5]. Exostoses develop shortly after birth and continue to develop throughout childhood and puberty [6]. Malignant degeneration is the most severe complication [6].

Osteochondroma may cause various complications such as arterial pseudo-aneurysms. The vascular disease genesis is due to repeated exercices, such a s knee flexion which could chronically abrad the popliteal artery and produce an adventicial defect followed by a pseudo-aneurysm. [7]

Exostose is often asymptomatic. A chronic edema may reveal popliteal artery disease. It may also lead to many other problems: peripheral nerves compression, blood vessels, distal ischemia,

phlebitis and pulsative mass [8]. In our case, the pseudo-aneurysm was revealed by the rupture which occurred during surgery: While the exostose was being removed, a false aneurysm with arterial bleeding was found. In this case report, osteochondroma was removed without arteriography.

In addition to this patient, 2 other cases of rupture of popliteal artery have been reported in the literature. The pathologic diagnosis of osteochondroma is made by radiographic examination which demonstrated an osteocartilaginous exostosis [9]. The clinical diagnosis of a false aneurysm was confirmed by a digitalized arteriography or vascular ultrasonography.

The first case is a 33 -year -old patient. Osteochondroma was located on the fibula.The rupture occurred after traumatisme .the popliteal artery was repaired by vein patch angioplasty [10]. The second case is a 20 -year -old patient; the exostose was located on the tibia. The rupture came after a sport's accident. The artery was repaired by veinous graft.

In our patient, the exostosis was removed by an orthopaedic surgeon. No vascular ultrasonography or arteriography have been realized before surgery. After removing the exostosis, bleeding occurred and a ligation of the popliteal artery was reported by the orthopaedic surgeon. A part from the surgery, there was no history of trauma that might have caused a fracture of the exostosis. Pain, edema, pulsative mass are the most frequent pseudo-aneurysm clinical signs. However, the rupture may reveal a pseudo-aneurysm not yet known. In this case, surgery is required.

Surgical repair and excision of the adjacent osteochondroma is considered as the treatment of choice. One case of successful transarterial embolization using helical microcoils in the treatment of pseudoaneurysm on osteochondroma that was located on the superficial femoral artery. The popliteal artery aren't suitable to this kind of treatment. Our patient is young, the pseudoaneurysm was broken when he was admitted to our hospital and the popliteal artery was ligated by the orthopaedic surgeon. So, surgery was required to restitute a normal vascular status.

## Conclusion

---

Osteochondroma may be present as a solitary lesion or in the form of hereditary multiple exostoses. Vascular complications of exososes are infrequent and the association with false aneurysms is exceptional. Acute rupture is rare, In a recent review of the literature, 38 cases of popliteal pseudoaneurysm secondary to exostosis have been reported, and only two of which were ruptured. To our knowledge this is the first case of intraoperative rupture occurring during resection surgery for distal femur osteochondroma. A combined orthopaedic and vascular surgery must always be undertaken when there is exostose associated to a false aneurysme.

## Competing interests

---

The authors declare that they have no conflict of interests.

## Authors' contributions

---

Rita Hajji et Abdellatif Bouarhroum: Redaction of the paper. All authors of this paper have read and approved the final version submitted.

## Figures

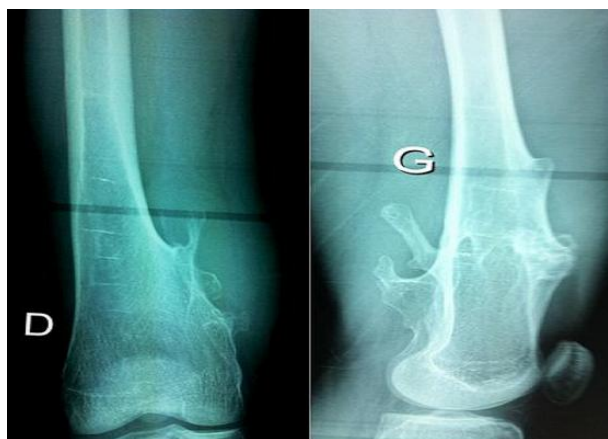**Figure 1:** X-ray of the knee showing the bilateral exostoses of distal femur

**Figure 2:** Pre-operative Digital subtraction arteriography showing the popliteal artery occlusion

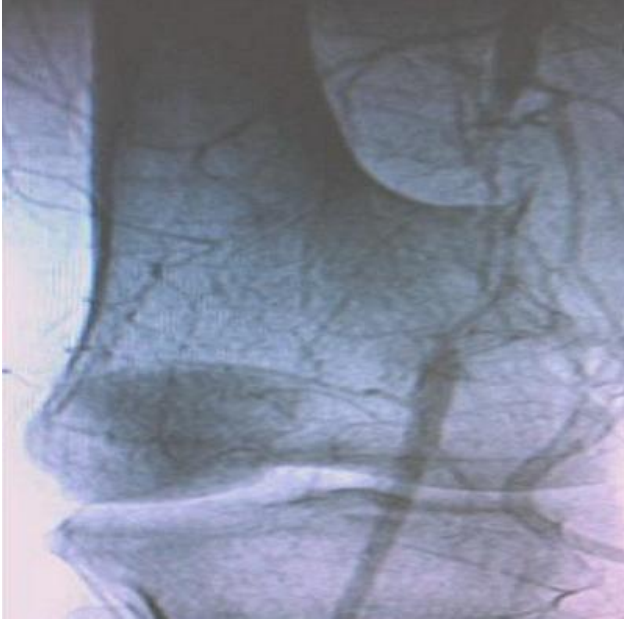**Figure 3:** Intraoperative image: popliteal artery repaired with a reversed saphenous vein interposition graft

## References

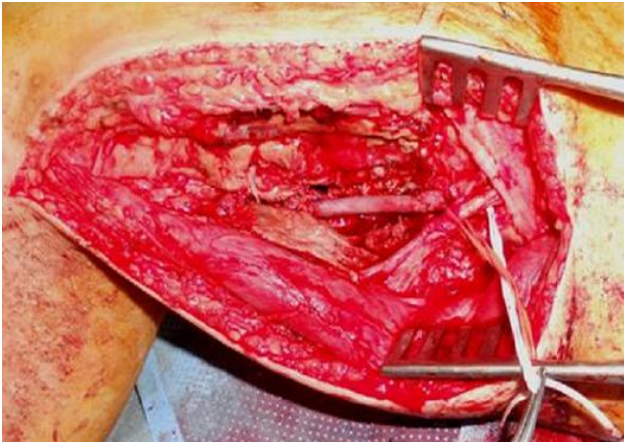
1. Jones KB, Morcuende JA. Of hedgehogs and hereditary bone tumors: re-examination of the pathogenesis of osteochondromas. *Iowa Orthop J.* 2003; 23:87-95. [PubMed](#) | [Google Scholar](#)
2. Murphy MD, Choi JJ, Kransdorf MJ, et al. Imaging of osteochondroma: variants and complications with radiologic? Pathologic correlations. *Radiographics.* 2000; 20(5):1407-3. [PubMed](#) | [Google Scholar](#)
3. Antonio ZP, Alejandro RM, Luis MR, José GR. Femur osteochondroma and secondary pseudoanevrysm of the popliteal artery. *Arch Orthop Trauma Surg.* 2006; 126(2):127-130. [Google Scholar](#)
4. Schmale GA, Conrad EU, Raskind WH. The natural history of hereditary multiple exostoses. *J Bone Joint Surg [Am].* 1994; 76(7):986-92. [Google Scholar](#)
5. Ahn J, Ludecke HJ, Lindow S, et al. Cloning of the putative tumor suppressor gene for hereditary multiple exostoses (EXT1) *Nature Genet.* 1995; 11(2):137-143. [PubMed](#) | [Google Scholar](#)
6. Legeai-Mallet L, Munnich A, Maroteaux P, et al. Incomplete penetrance and expressivity skewing in hereditary multiple exostoses. *Clin Genet.* 1997; 52(1):12-6. [PubMed](#) | [Google Scholar](#)
7. Lesser AJ, Greely GA, Deely DM. Osteochondroma: an usual cause of vascular disease in young adults. *J Vasc Intervent Radiol.* 1995; 6(4):605-13. [Google Scholar](#)
8. Vasseur MA, Fabre O. Vascular complications of osteochondromas. *J Vasc Surg* 2000; 31(3):532-8. [PubMed](#) | [Google Scholar](#)
9. Murphey MD, Choi JJ, Kransdorf MJ, Flemming DJ, Gannon FH. Imaging of osteochondroma: variants and complications with radiologic-pathologic correlation. *Radiographics.* 2000. <http://radiographics.highwire.org/content/20/5/1407.full.pdf+html>. Accessed 16th December 2013. [Google Scholar](#)
10. Ballaro A, Fox AD, Collin J. Rupture of a popliteal artery pseudoanevrysm secondary to a fibular osteochondroma. *Eur J Vasc Endovasc Surg.* 1997; 14(2):151-2. [Google Scholar](#)



**Figure 1:** X-ray of the knee showing the bilateral exostoses of distal femur



**Figure 2:** Pre-operative Digital subtraction arteriography showing the popliteal artery occlusion



**Figure 3:** Intraoperative image: popliteal artery repaired with a reversed saphenous vein interposition graft