

# Images in medicine

## A tongue ulcer



**Aryé Weinberg<sup>1,&</sup>, Ralf Siegert<sup>1</sup>**

<sup>1</sup>Prosper-Hospital, Department of Otorhinolaryngology, Head and Neck Surgery, Recklinghausen, Germany

<sup>&</sup>Corresponding author: Aryé Weinberg, Prosper-Hospital, Department of Otorhinolaryngology, Head and Neck Surgery, Recklinghausen, Germany

Key words: Tongue ulcer, pressure ulcer, sharp tooth surface

Received: 29/01/2018 - Accepted: 07/05/2018 - Published: 16/05/2018

**Pan African Medical Journal. 2018; 30:31 doi:10.11604/pamj.2018.30.31.15007**

This article is available online at: <http://www.panafrican-med-journal.com/content/article/30/31/full/>

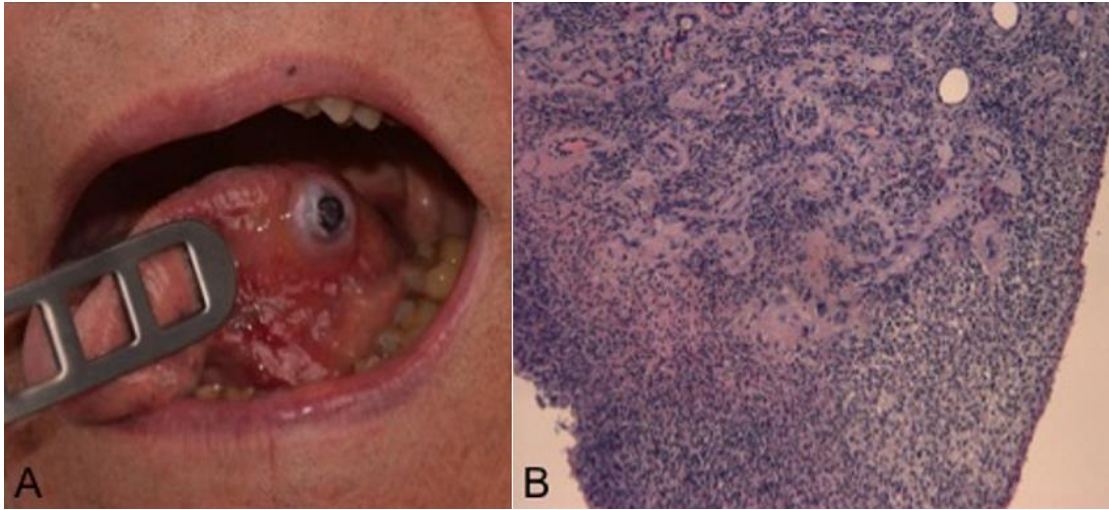
© Aryé Weinberg et al. The Pan African Medical Journal - ISSN 1937-8688. This is an Open Access article distributed under the terms of the Creative Commons Attribution License (<http://creativecommons.org/licenses/by/2.0>), which permits unrestricted use, distribution, and reproduction in any medium, provided the original work is properly cited.

### Image in medicine

---

An 86-year-old man presented with a painful lesion on his left tongue measuring 0.6 x 0.6mm (A). The lesion has been growing over the last 2 weeks. The patient did not remember any trauma except that his teeth did sometimes scratch his tongue. Histology from the excised lesion revealed a pressure ulcer (B). Tongue ulcers can be caused by accidental bites, ill-fitting dentures, braces, citrus

or acidic fruits and by a sharp tooth surface. In some other cases nutritional problems such as vitamin B12, iron or folic acid deficiency may cause tongue ulcers. Never the less malignancy needs to be excluded. Therefore, complete excision and diagnosis based on histology is recommended.



**Figure 1:** A) tongue lesion; B) pressure ulcer