

Images in medicine

Mirroring spinal cord lesion secondary to B12 deficiency



Youssef Benmoh¹, Ahmed Bourazza¹

¹Department of Neurology, Military Hospital MOHAMED V, Rabat, Morocco

⁸Corresponding author: Youssef Benmoh. Department of Neurology, Military Hospital MOHAMED V, Rabat, Morocco

Key words: B12 deficiency, combined sclerosis, spinal cord, MRI

Received: 04/02/2017 - Accepted: 07/03/2017 - Published: 07/03/2017

Pan African Medical Journal. 2017;26:130. doi:10.11604/pamj.2017.26.130.11853

This article is available online at: <http://www.panafrican-med-journal.com/content/article/26/130/full/>

© Youssef Benmoh et al. The Pan African Medical Journal - ISSN 1937-8688. This is an Open Access article distributed under the terms of the Creative Commons Attribution License (<http://creativecommons.org/licenses/by/2.0>), which permits unrestricted use, distribution, and reproduction in any medium, provided the original work is properly cited.

Image in medicine

A 26 year-old girl, previously healthy, admitted for progressive weakness of both lower limbs, with permanent paresthesia evolving for 6 months. Clinical examination found spastic paraparesis with proprioceptive ataxia. The MRI showed bilateral and symmetrical lesions in the cervical spinal cord. Lesions were T1-isointense and T2 hyperintense, located on both lateral and posterior funiculus without enhancement. Investigation revealed deep vitamin B12 deficiency (27pg/ml), macrocytosis, with positive parietal cell-antibody and fundic gastritis. Patient was treated with intra muscular hydroxycobalamin. Evolution was favorable with regression of weakness and paresthesia of both lower limbs, and persistence of discreet ataxia. Cobalamin deficiency is common in the elderly. It causes hematologic, digestive and neurological disorders. Neurological signs are dominated by combined sclerosis of the spinal cord, and peripheral neuropathy. MRI is useful in front of myelopathy, showing an enlargement or T2-hyperintense lesion of the posterior funiculus.

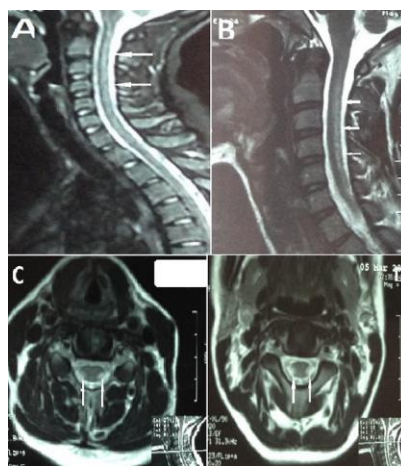


Figure 1: (A,B) MRI of the spinal cord, in sagittal T2 weighted image showing an increased signal intensity extended to the whole cervical spinal cord; (C ,D) MRI of the spinal cord, in axial T2 weighted image, showing increased bilateral and symmetrical signal intensity of lateral and posterior funiculus.