



Images in medicine

A rare cause of digital clubbing: pachydermoperiostosis

Zeineb Alaya^{1,8}, Walid Osman²

¹Department of Rheumatology, Farhat Hached Hospital, Faculty of Medicine of Sousse, Sousse, Tunisia, ²Department of Orthopaedics, Sahloul Hospital, Faculty of Medicine of Sousse, Sousse, Tunisia

⁸Corresponding author: Zeineb Alaya, Department of Rheumatology, Farhat Hached Hospital, Faculty of Medicine of Sousse, Sousse, Tunisia

Key words: Pachydermoperiostosis, digital clubbing, thickening of the skin

Received: 06/10/2016 - Accepted: 16/10/2016 - Published: 25/11/2016

Pan African Medical Journal. 2016; 25:194 doi:10.11604/pamj.2016.25.194.10890

This article is available online at: <http://www.panafrican-med-journal.com/content/article/25/194/full/>

© Zeineb Alaya et al. The Pan African Medical Journal - ISSN 1937-8688. This is an Open Access article distributed under the terms of the Creative Commons Attribution License (<http://creativecommons.org/licenses/by/2.0>), which permits unrestricted use, distribution, and reproduction in any medium, provided the original work is properly cited.

Image in medicine

A 35-year-old man of Tunisian origin complained of inflammatory arthralgia and he had noticed a progressive enlargement of his hands and feet as well as facial furrowing. On examination, he had thickening of the skin of the head and distal extremities and deep folds and furrows of the skin of the forehead (A), digital clubbing of fingers (B) and toes (C), spadelike enlargement of the hands and feet, hyperhidrosis of the hands and feet and seborrhea. Inflammation tests were disturbed. Radiographs showed periostosis of the long bones (D) and sacro-iliac osteosclerosis. After excluding secondary causes, primary hypertrophic osteoarthropathy also called pachydermoperiostosis (PDP) was established. This disease is characterised by thickening of the skin of the head and distal extremities, deep folds and furrows of the skin of the forehead, cheeks, and scalp, seborrhea; hyperhidrosis; periostosis of the long bones and digital clubbing. The treatment consisted in our case of analgesics and NSAIDs.

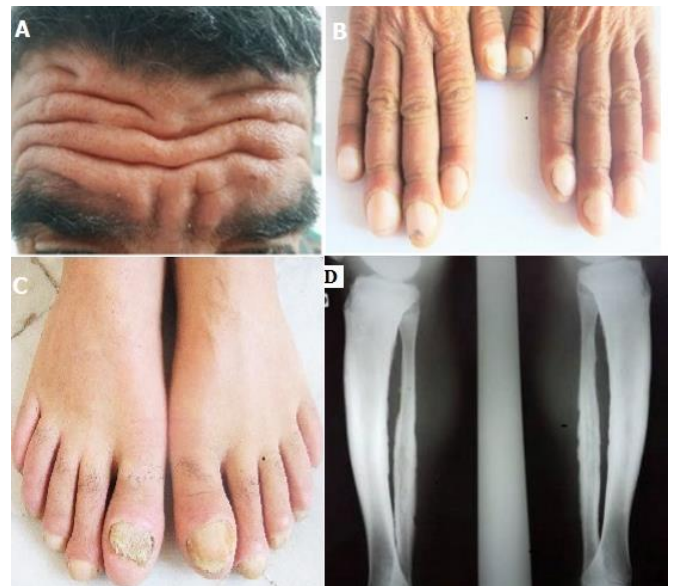


Figure 1: A) thickening of the skin of the head and deep folds and furrows of the skin of the forehead; B) digital clubbing of fingers; C) digital clubbing of toes; D) periostosis of the long bones