

Images in medicine

Réaction sclérale pseudotumorale au fil de polyester téréphtalique tressé et aux cils pris accidentellement après chirurgie de décollement de rétine en ab-externo



Pseudotumoral scleral reaction to terephthalic braided polyester filament and to eyelashes accidentally retained after ab externo surgery for retinal detachment

Sophia El Hamichi^{1,&}, Abdelbarre Oubaz¹

¹Military Hospital Mohammed V of Rabat, Rabat, Morocco

[&]Corresponding author: Sophia El Hamichi, Military Hospital Mohammed V of Rabat, Rabat, Morocco

Mots clés: Reaction pseudotumorale, décollement de rétine, chirurgie ab-externo

Received: 30/01/2016 - Accepted: 17/02/2016 - Published: 20/10/2016

Pan African Medical Journal. 2016; 25:101 doi:10.11604/pamj.2016.25.101.8980

This article is available online at: <http://www.panafrican-med-journal.com/content/article/25/101/full/>

© Sophia El Hamichi et al. The Pan African Medical Journal - ISSN 1937-8688. This is an Open Access article distributed under the terms of the Creative Commons Attribution License (<http://creativecommons.org/licenses/by/2.0>), which permits unrestricted use, distribution, and reproduction in any medium, provided the original work is properly cited.

Image en médecine

The objective of this study were to highlight a new postoperative complication after surgery for retinal detachment. We report the case of a 50-year old patient with pseudotumoral scleral reaction to eyelashes and to MERSUTURE filament occurred several months after surgery for retinal detachment. Eyelashes were accidentally retained due to surgeon's inattention. The result was confirmed by anatomo-pathological examination. This is a complication due to surgeon's inattention.*

Key words: Pseudotumoral reaction, retinal detachment, ab-externo surgery.

Il s'agit d'une réaction pseudotumorale aux cils et au fil de MERSUTURE+ survenue plusieurs mois après chirurgie de décollement de rétine, chez un patient de 50 ans. Les cils ont été pris accidentellement et par inattention du chirurgien opérateur. Le résultat était confirmé à l'examen anatomopathologique.

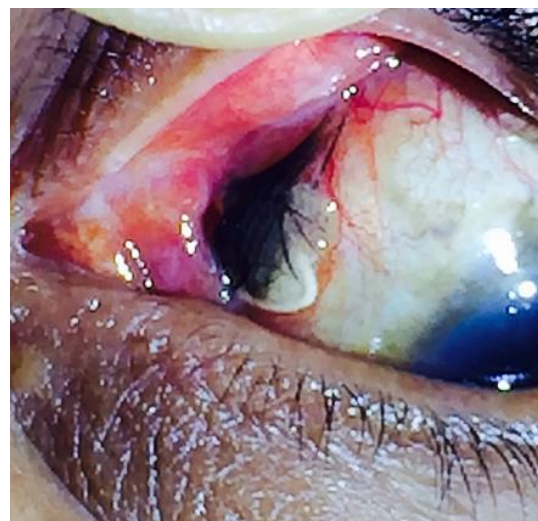


Figure 1: réaction pseudotumorale au fil de MERSUTURE+ et aux cils