



Images in medicine

Macular scar secondary to congenital toxoplasmosis

Sophia El Hamichi^{1,&}, Abdelbarre Oubaz¹

¹Military Hospital Mohammed V of Rabat, Rabat, Morocco

[&]Corresponding author: Sophia El Hamichi, Military Hospital Mohammed V of Rabat, Rabat, Morocco

Key words: Macular scar, congenital toxoplasmosis, strabismus

Received: 30/01/2016 - Accepted: 17/02/2016 - Published: 24/08/2016

Pan African Medical Journal. 2016; 24:325 doi:10.11604/pamj.2016.24.325.8981

This article is available online at: <http://www.panafrican-med-journal.com/content/article/24/325/full/>

© Sophia El Hamichi et al. The Pan African Medical Journal - ISSN 1937-8688. This is an Open Access article distributed under the terms of the Creative Commons Attribution License (<http://creativecommons.org/licenses/by/2.0>), which permits unrestricted use, distribution, and reproduction in any medium, provided the original work is properly cited.

Image in medicine

An 8 years old girl suffers from strabismus since her first months of life. Her visual acuity was very low and could only see fingers moving in her left eye. Her left eye fundus showed a chorioretinal scar in the macula due to congenital toxoplasmosis. The biological findings proved the diagnosis of congenital toxoplasmosis. Functional prognosis of macular scars is very dark.

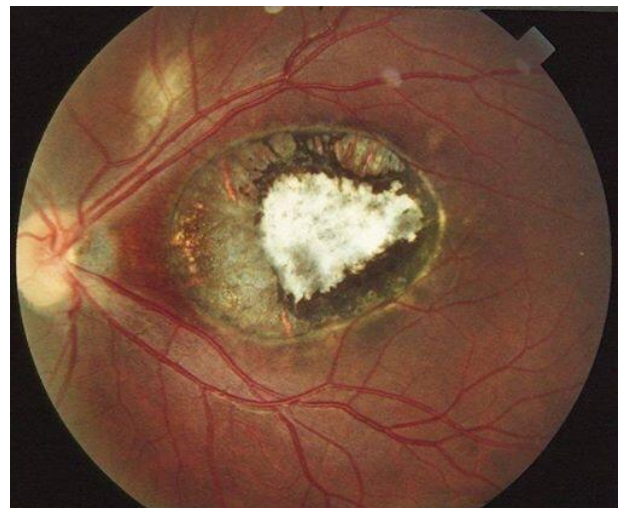


Figure 1: retinography showing a macular retinochoroidal scar secondary to toxoplasmosis