

## Case report

### Intertrochanteric fracture non-unions with implant failure of the gamma nail

Mouhcine Sbiyaa<sup>1,§</sup>, Adil El Alaoui<sup>1</sup>, Mohammed Admi<sup>1</sup>, Kamal Lahrach<sup>1</sup>, Amine Marzouki<sup>1</sup>, Fawzi Boutayeb<sup>1</sup>

<sup>1</sup>Service de Chirurgie Orthopédique et Traumatologique (A), Pr F. Boutayeb, CHU Hassan II de Fès, Maroc

<sup>§</sup>Corresponding author: Mouhcine Sbiyaa, Service de Chirurgie Orthopédique et Traumatologique (A), Pr F. Boutayeb, CHU Hassan II de Fès, Maroc

Key words: intertrochanteric fracture, complication, fracture non union

Received: 16/09/2015 - Accepted: 08/01/2016 - Published: 29/02/2016

#### Abstract

Failure of internal fixation of intertrochanteric fracture is associated with delayed union or malunion resulting in persistent pain and diminished function. We report a rare case of implant failure of the gamma nail with intertrochanteric fracture non union treated by DCS plate screw and bone graft.

**Pan African Medical Journal. 2016; 23:57 doi:10.11604/pamj.2016.23.57.7965**

This article is available online at: <http://www.panafrican-med-journal.com/content/article/23/57/full/>

© Mouhcine Sbiyaa et al. The Pan African Medical Journal - ISSN 1937-8688. This is an Open Access article distributed under the terms of the Creative Commons Attribution License (<http://creativecommons.org/licenses/by/2.0>), which permits unrestricted use, distribution, and reproduction in any medium, provided the original work is properly cited.

## Introduction

---

Intertrochanteric fractures account for 10-34% of all hip fractures [1, 2]. The incidence of pertrochanteric femoral shaft fractures has a bimodal age distribution, affecting young patients following high-energy trauma (resulting in significant fracture comminution) and older patients after low velocity trauma secondary to osteoporosis or metastatic pathological lesions [3, 4]. The gamma interlocking nail was designed especially for the treatment of unstable peri and subtrochanteric femoral fractures [5, 6]. It combines the advantage of the sliding hip screw, a locked intramedullary implant with a lower bending moment, and increased length- and rotational stability [7, 8]. Because of its material strength, design, and mechanical advantage [9, 10] implant failure of the Gamma nail has been thought to be rare. We present a rare case of implant failure of the Gamma nail.

## Patient and observation

---

The patient was a 67-year-old female with a good life quality, who presented an unstable intertrochanteric fracture of his left femur, Kyle and Gustilo type III following a fall at home. She underwent surgical fixation of his fracture with a short trochanteric Gamma nail, with a cervico diaphyseal angle of 130° and a distal diameter of 11 mm. The cephalic screw was 90 mm long; proximal static locking was performed. Postoperative radiographs showed acceptable reduction of the fracture. Four months later, the patient started complaining of permanent pain in his left hip, which became more severe over a few days, resulting in complete disability. He did not recall any trauma or unusual efforts. On physical examination, there was pain on palpation of the left trochanter as well as on mobilisation, particularly in rotation. The surgical wound was unremarkable. Radiographs showed breakage of the nail, at the opening for the cervical screw (Figure 1), resulting in an angulation between the nail and the cephalic screw. The fracture showed no signs of healing; the fracture line was still visible, with sclerosis of the bone ends, typical for a nonunion. The broken nail was removed (Figure 2, Figure 3) and a DCS plate screw was implanted with bone graft levied from the iliac crest (Figure 4, Figure 5, Figure 6). Early weight-bearing was encouraged. All bacteriological samples taken were sterile. Two months later, radiographs showed healing

of the fracture (Figure 7). The patient is presently asymptomatic, walking without help.

## Discussion

---

Unstable peri and subtrochanteric fractures of the proximal femur are complicated by the massive tension moments laterally and compressive forces medially created by the weight of the body, hip flexors and external rotators and by the abductor musculature, resulting often in fracture displacement, loss of fixation and implant failure [11, 12]. The gamma nail proved to be an adequate implant to stabilize stable and unstable peri- and subtrochanteric fractures. In the recent literature, the incidence of intraoperative fracture of the shaft was reported to be decreased because of the modification of implant design and the improvement of surgical technique [13-16]. The reported incidence of implant failure of the Gamma nail is 0%-0.4% in multicenter studies [17-19]. In a series of 2500 Gamma nail fixations, only 4 (0.16%) nails broke, all associated with nonunion and continued weight bearing. Breakage time varied from postoperative month 6 to 15, suggesting fatigue caused by dynamic loading [19]. A weak point in the Gamma nail seems to be around the opening for the cephalic screw, where the cross section narrows, approximately by 73% [20]. This is the critical zone where forces coming from the femoral neck are transmitted to the diaphyseal nail [19, 21]. If the guide for the cervical screw is not properly placed, inappropriate drilling of the nail or off-centre introduction of the cervical screw may cause erosion of the nail in the cervical opening. This complication usually occurs late, 6 to 10 months after surgery. Thus, the possibility of the implant being broken when there is recurring pain at the operated hip or even more frequently at the thigh must be taken into consideration. Special attention must be paid to those cases with pathological fractures [22]. We recommend taking radiographs of the operated hip in two different projections in the follow-ups and the option of dynamisation of the device and/or bone grafting must always be considered when delayed union is suspected. The options for treatment will depend on each particular situation. Retrieving the implant may be very difficult, especially the distal fragment of the broken nail. It may be necessary to open a window in the diaphyseal cortex. For this reason, we recommend a careful preoperative planning and rigorous technique that will avoid problems with the screws, both proximal and distal.

## Conclusion

---

Breakage of the Gamma nail due to fatigue is a very rare complication. It occurs 6 to 10 months after surgery. It is a consequence of nonunion at the fracture site. The weakest point of the Gamma nail is the opening for the cervical screw. The best therapeutic option will depend on each particular situation.

## Competing interests

---

The authors declare no competing interest.

## Authors' contributions

---

All the authors cited in this article have contributed in the management of the patient or write-up of the manuscript. All the authors have read and approved the final version of the manuscript.

## Figures

---

**Figure 1:** Antero-posterior radiograph of the left hip 6 months after stabilisation of peritrochanteric fracture with a gamma nail

**Figure 2:** Intra-operative antero-posterior radiograph of material ablation

**Figure 3:** Fracture of gamma nail

**Figure 4:** Intra-operative picture illustrating stabilisation of the non-union

**Figure 5:** Bone graft levied from the iliac crest

**Figure 6:** Intra-operative antero-posterior radiograph of the revision fixation

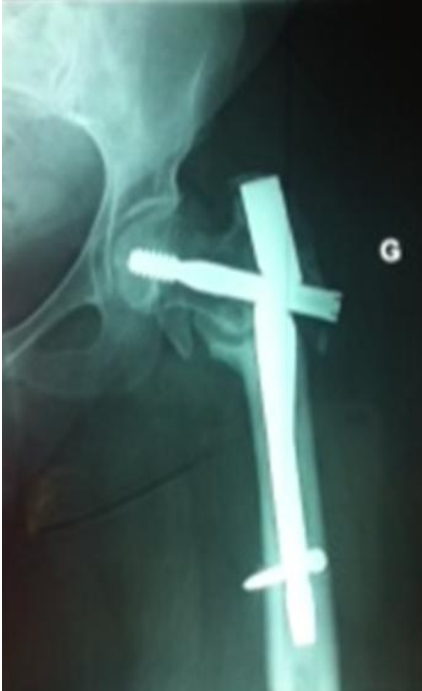**Figure 7:** Antero-posterior radiograph of the left proximal femur showing the union of the fracture

## References

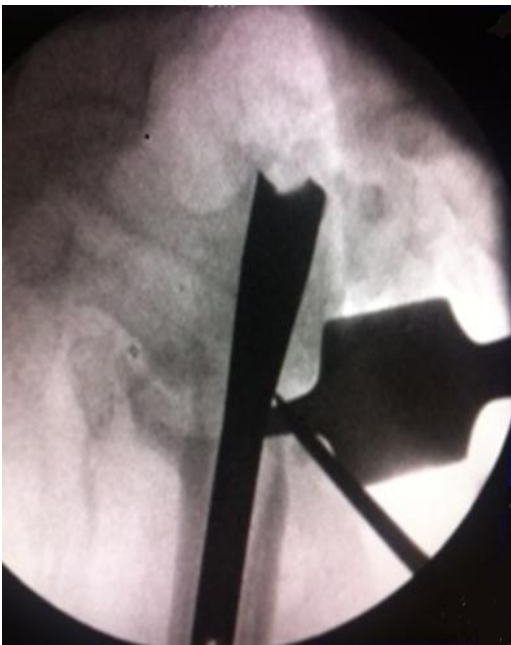
---

1. Yli-Kyyry TT, Sund R, Juntunen M, Salo JJ, Kroger HP. Extra- and intramedullary implants for the treatment of peritrochanteric fractures—results from a Finnish National Database Study of 14,915 patients. *Injury*. 2012 Dec; 43(12): 2156-60. **PubMed | Google Scholar**
2. Loizou CL, McNamara I, Ahmed K, Pryor GA, Parker MJ. Classification of subtrochanteric femoral fractures. *Injury*. 2010 Jul;41(7):739-45. **PubMed | Google Scholar**
3. Kennedy MT, Mitra A, Hierlihy TG, Harty JA, Reidy D, Dolan M. Subtrochanteric hip fractures treated with cerclage cables and long cephalomedullary nails: a review of 17 consecutive cases over 2 years. *Injury*. 2011; 42(11): 1317-21. **PubMed | Google Scholar**
4. Kuzyk PR, Bhandari M, McKee MD, Russell TA, Schemitsch EH. Intramedullary versus extramedullary fixation for subtrochanteric femur fractures. *J Orthop Trauma*. 2009 Jul; 23(6): 465-70. **PubMed | Google Scholar**
5. Halder SC. The gamma nail for peritrochanteric fractures. *J Bone Joint Surg Br*. 1992 May;74(3):340-4. **PubMed | Google Scholar**
6. Heinz T, Vecsei V. The gamma nail. A new implant for the management of hip para-articular fractures. *Aktuelle Traumatol*. 1992 Aug; 22(4): 163-9. **PubMed | Google Scholar**
7. Aune AK, Ekland A, Odegaard B et al. Gamma nail vs compression screw for trochanteric femoral fractures. *Acta Orthop Scand*. 1994 Apr;65(2):127-30. **PubMed | Google Scholar**
8. Radford PJ, Needoff M, Webb JK. A prospective randomized comparison of the dynamic hip screw and the gamma locking nail. *J Bone Joint Surg Br*. 1993 Sep; 75(5): 789-93. **PubMed | Google Scholar**

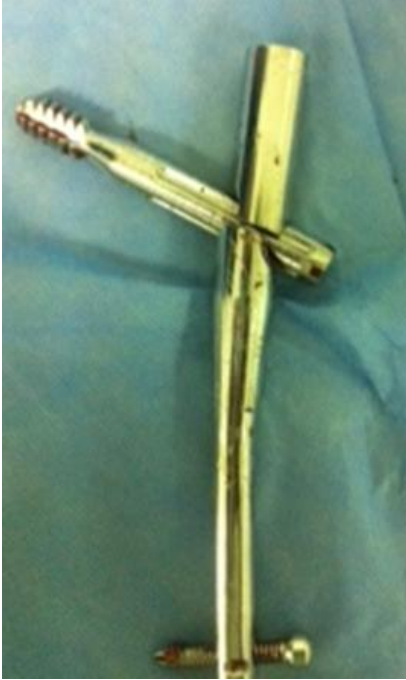9. Leung KS, So WS, Shen WY, Hui PW. Gamma nails and dynamic hip screws for peritrochanteric fractures. *J Bone Joint Surg Br.* 1992 May; 74(3): 345-51. **PubMed | Google Scholar**
10. Rosenblum SF, Zuckerman JD, Kummer FJ, Tam BS. A biomechanical evaluation of the Gamma nail. *J Bone Joint Surg Br.* 1992 May; 74(3): 352-7. **PubMed | Google Scholar**
11. Lindsey RW, Teal P, Probe RA et al. Early experience with the gamma interlocking nail for peritrochanteric fractures of the proximal femur. *J Trauma.* 1991 Dec; 31(12): 1649-58. **PubMed | Google Scholar**
12. Vanderschot P, Vanderspeeten K, Verheyen L et al. A review on 161 subtrochanteric fractures-risk factors influencing outcome: age, fracture pattern and fracture level. *Unfallchirurg.* 1995 May; 98(5): 265-71. **PubMed | Google Scholar**
13. Bellabarba C, Herscovici D Jr, Ricci WM. Percutaneous treatment of peritrochanteric fractures using the Gamma nail. *Clin Orthop Relat Res.* 2000 Jun; (375): 30-42. **PubMed | Google Scholar**
14. Leung KS, So WS, Shen WY, Hui PW. Gamma nails and dynamic hip screws for peritrochanteric fractures. *J Bone Joint Surg Br.* 1992; 74(3): 345-51. **PubMed | Google Scholar**
15. Habernek H, Wallner T, Aschauer E, Schmid L. Comparison of Ender nails, dynamic hip screws, and Gamma nails in the treatment of peritrochanteric femoral fractures. *Orthopedics.* 2000; 23(2): 121-7. **PubMed | Google Scholar**
16. Kukla C, Heinz T, Gaebler C, Heinze G, Vécsei V. The standard Gamma nail: a critical analysis of 1000 cases. *J Trauma.* 2001; 51(1): 77-83. **PubMed | Google Scholar**
17. Boriani S, De Iure F, Bettelli G, Specchia L, Bungaro P, Montanari G et al. The results of a multicenter Italian study on the use of the Gamma nail for the treatment of peritrochanteric and subtrochanteric fractures: a review of 1181 cases. *Chir Organi Mov.* 1994; 79(2): 193-203. **PubMed | Google Scholar**
18. Gaebler C, Stanzl-Tschegg S, Tschegg EK, Kukla C, Menth-Chiari WA, Wozasek GE et al. Implant failure of the Gamma nail. *Injury.* 1999; 30(2): 91-9. **PubMed | Google Scholar**
19. Van den Brink WA, Janssen IMC. Failure of the Gamma nail in a highly unstable proximal femur fracture: report of four cases encountered in The Netherlands. *J Orthop Trauma.* 1995; 9(1): 53-6. **PubMed | Google Scholar**
20. Zafiroopoulos G, Pratt DJ. Fractured Gamma nail. *Injury.* 1994; 25(5): 331-336. **PubMed | Google Scholar**
21. Seral B, García JM, Cegoñino J, Doblaré M, Seral F. Finite element study of intramedullary osteosynthesis in the treatment of trochanteric fractures of the hip: Gamma and PFN. *Injury.* 2004 Feb; 35(2): 130-5. **PubMed | Google Scholar**
22. Randle JA, Meisami-Fard B, McKee MD. Mechanical failure of a Gamma nail in a patient with an impending pathologic subtrochanteric fracture. *Can J Surg.* 1999 Oct; 42(5): 384-6. **PubMed | Google Scholar**



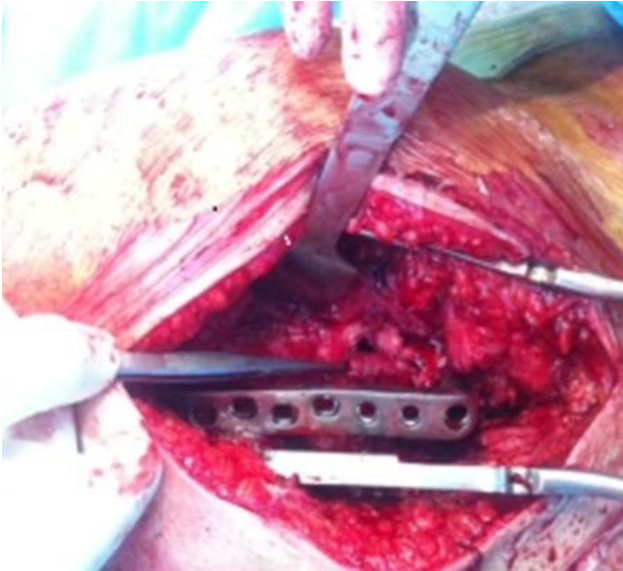
**Figure 1:** Antero-posterior radiograph of the left hip 6 months after stabilisation of peritrochanteric fracture with a gamma nail



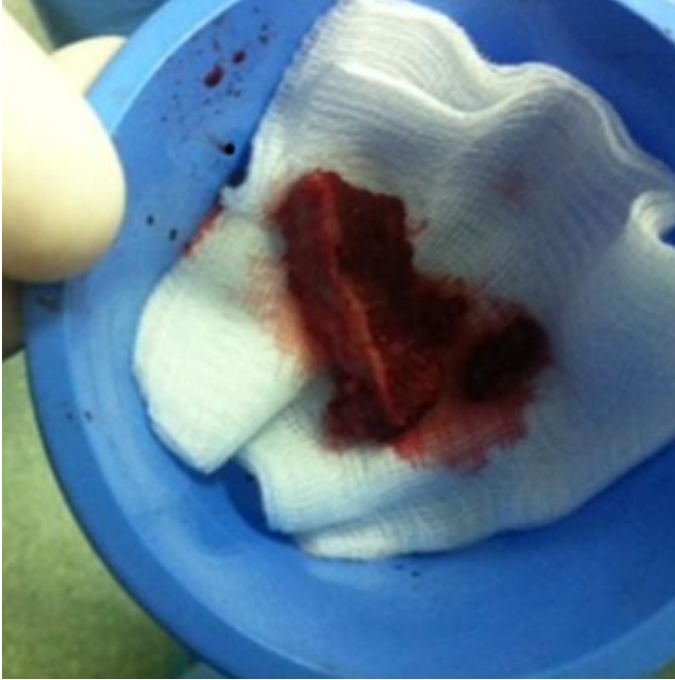**Figure 2:** Intra-operative antero-posterior radiograph of material ablation



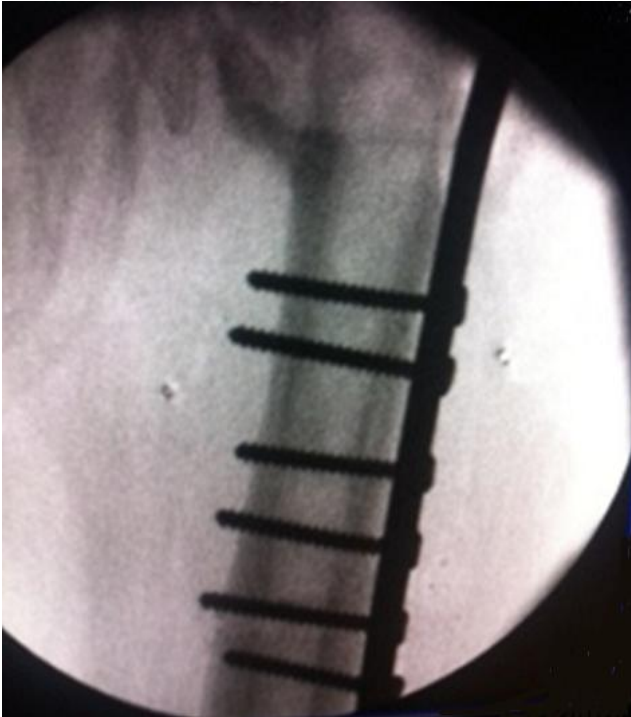**Figure 3:** Fracture of gamma nail



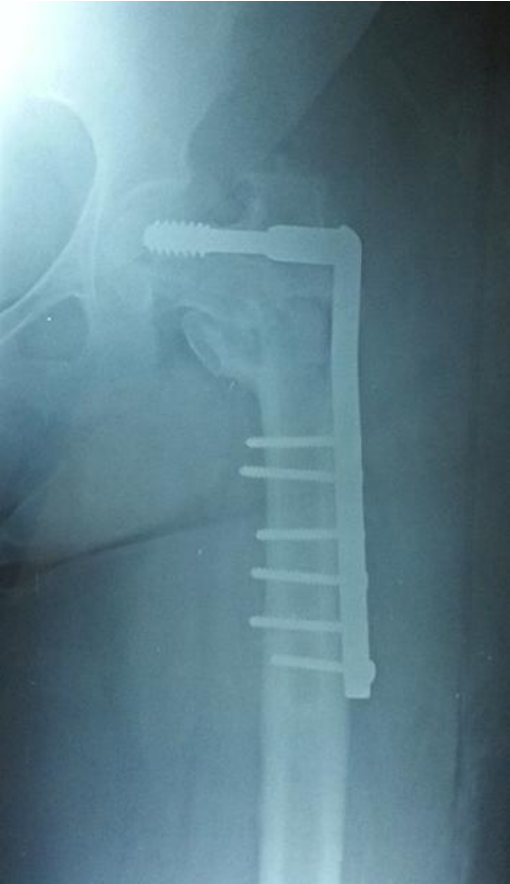**Figure 4:** Intra-operative picture illustrating stabilisation of the non-union



**Figure 5:** Bone graft levied from the iliac crest



**Figure 6:** Intra-operative antero-posterior radiograph of the revision fixation



**Figure 7:** Antero-posterior radiograph of the left proximal femur showing the union of the fracture