

Images in medicine

Dermoscopy in atypical phthiriasis eyelash

Krich Sanaa^{1,*}, Mernissi Fatima Zahra¹

¹Dermatological Department, Hassan II university Hospital, Fes, Morocco

*Corresponding author: Krich Sanaa, Dermatological Department, Hassan II university Hospital, Fes, Morocco

Key words: Phthiriasis, eyelash, dermoscopy

Received: 02/12/2015 - Accepted: 31/12/2015 - Published: 22/01/2016

Pan African Medical Journal. 2016; 23:11 doi:10.11604/pamj.2016.23.11.8541

This article is available online at: <http://www.panafrican-med-journal.com/content/article/23/11/full/>

© Krich Sanaa et al. The Pan African Medical Journal - ISSN 1937-8688. This is an Open Access article distributed under the terms of the Creative Commons Attribution License (<http://creativecommons.org/licenses/by/2.0>), which permits unrestricted use, distribution, and reproduction in any medium, provided the original work is properly cited.

Image in medicine

A 47 year-old male, with no history of pathological notables who present since 3 years chronic and severe itching eyelids pushing the patient to remove her eyelashes. Examination of the eyelids objectified a madarosis with irritation of eyelids (A). Dermoscopic examination revealed the presence of nits attached to the eyelashes (B). There was any lesions on the examination of other body areas. Based on the observation of nits at the base of the eyelashes (C) a diagnosis of phthiriasis palpebrarum was mad. Patient was treated with oral ivermectin associated to hygiene measure. Phthiriasis palpebrarum (lice infestation of eyelids), caused by the *Phthirus pubis*, is an unusual cause of blepharitis and conjunctivitis and may easily be overlooked because of the failure of physicians to recognize *P. pubis*. Dermoscopy can aid in the detection of nits and in monitoring treatment response by determining whether nits contain viable or dead nymphs or are empty (D).

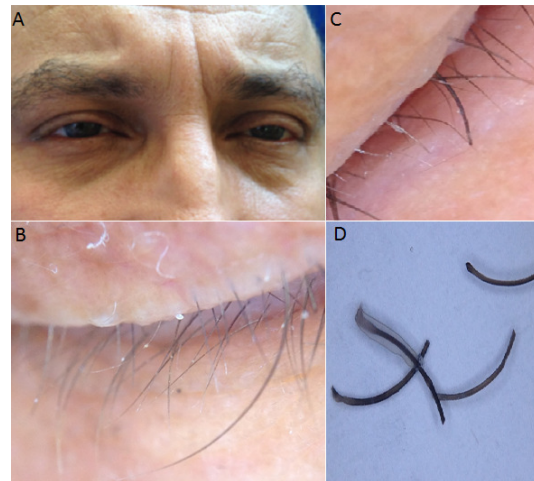


Figure 1: (A) madarosis with irritation of eyelids; (B) presence of nits attached to the eyelashes; (C) nits at the base of the eyelashes; (D) amorphous pseudonits attached to the hair shaft