

# Images in medicine

## Amoebic pleuropericarditis

Abdellah Amine<sup>1, &</sup>, Jamal Fatihi<sup>2</sup>

<sup>1</sup>Cardiology, 5th Military Hospital Guelmim, Guelmim, Morocco, <sup>2</sup>Medicine, 5th Military Hospital Guelmim, Guelmim, Morocco

<sup>&</sup>Corresponding author: Abdellah Amine, Cardiology, 5th Military Hospital Guelmim, Guelmim, Morocco

Key words: Amoebiasis, pericarditis, edema

Received: 28/09/2015 - Accepted: 12/10/2015 - Published: 02/12/2015

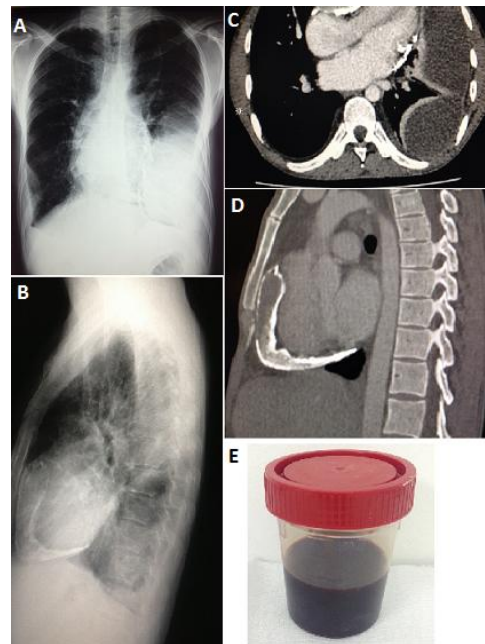
**Pan African Medical Journal. 2015; 22:323 doi:10.11604/pamj.2015.22.323.8058**

This article is available online at: <http://www.panafrican-med-journal.com/content/article/22/323/full/>

© Abdellah Amine et al. The Pan African Medical Journal - ISSN 1937-8688. This is an Open Access article distributed under the terms of the Creative Commons Attribution License (<http://creativecommons.org/licenses/by/2.0>), which permits unrestricted use, distribution, and reproduction in any medium, provided the original work is properly cited.

### Image in medicine

A 38-year-old man was admitted to the hospital for a 2-month gradually progressive history of breath shortness, persistent fever and leg swelling. Two years earlier, he had had a prolonged period of recurrent diarrhea which was spontaneously resolved. On examination temperature was 38.6°C with decreased breath sounds on the left side and leg pitting edema. Laboratory tests showed elevated inflammatory markers without leukocytosis. Chest X-ray revealed pleural effusion with extensive calcifications on the anterior and inferior surfaces of the heart. Thoracic computed tomography confirmed pleural effusion with pericardial thickening and calcification. Echocardiography was suggestive of constrictive pericarditis, thoracentesis revealed milk chocolate colored pleural fluid containing trophozoites of *Entamoeba Histolytica* with no mycobacterium or other organisms. The left pleural effusion was drained, patient was administrated Metronidazole IV 500 mg every 8 hours and has done well. Cardiac catheterization confirmed pericardial constriction, and patient received pericardectomy. Analysis Pathological of the surgical specimen did not find arguments for tuberculosis. We then selected the diagnostic of amoebic pleuro-pericarditis.



**Figure 1:** (A) face chest; (B) profil chest; (C) scanner chest; (D) profil scanner chest; (E) milk chocolate colored pleural fluid