

Case report

Ischemic cardiomyopathy revealed by central retinal artery occlusion (CRAO)

Ihsen Zairi^{1,8}, Khadija Mzoughi¹, Zouhayer Jnifene¹, Fethia Ben Moussa¹, Sofiene Kammoun¹, Sana Fennira¹, Nidhal Ben Moussa¹, Jihen Brour², Monia Cheour², SondosKraiem¹

¹Department of Cardiology, Habib Thameur public hospital, Bab el Fallah, Tunis, Tunisia, ²Department of Ophthalmology, Habib Thameur public hospital, Bab el Fallah, Tunis, Tunisia

⁸Corresponding author: Ihsen Zairi, Department of Cardiology, Habib Thameur public hospital, Bab el Fallah, Tunis, Tunisia

Key words: Central retinal artery occlusion, ischemic cardiomyopathy, cardiac thrombus

Received: 20/06/2015 - **Accepted:** 31/10/2015 - **Published:** 17/11/2015

Abstract

Here we report a case of central retinal artery occlusion revealing an ischemic cardiomyopathy. A 54-year old smoker man presented at the hospital because of sudden visual loss in his left eye. There was cherry-red spot in the macula in his left eye. We performed a fluorescein angiogram and cervical color Doppler. Later investigations revealed an ischemic cardiomyopathy undiagnosed until then.

Pan African Medical Journal. 2015; 22:250 doi:10.11604/pamj.2015.22.250.7308

This article is available online at: <http://www.panafrican-med-journal.com/content/article/22/250/full/>

© Ihsen Zairiet et al. The Pan African Medical Journal - ISSN 1937-8688. This is an Open Access article distributed under the terms of the Creative Commons Attribution License (<http://creativecommons.org/licenses/by/2.0>), which permits unrestricted use, distribution, and reproduction in any medium, provided the original work is properly cited.

Introduction

Central retinal artery occlusion is a rare but one of the ophthalmological emergency with worse prognosis that causes definite loss of vision within few hours of installation. Assimilated to the ocular analogue of cerebral stroke, it results on impaired functional capacity and quality of life. After initial measures, further investigations are necessary and can suggest the etiology of the CRAO.

Patient and observation

A 54-year-old man was admitted to Habib Thameur Hospital because of sudden loss of vision in the left eye from 12 hours. He is a smoker with no past medical history. Cardiovascular exam revealed no abnormalities. Color fundus photograph of the left eye showing acute CRAO with cherry-red spot and cattle trucking of the arteriole (**Figure 1**). Fundus fluorescein angiography showed a delayed arterial transit time (**Figure 2**). After 25 seconds from injection, there was no distal opacification. 180 seconds later, multiple intra-arterial emboli were noticed. Ophthalmologist concluded to a central retinal artery occlusion. After initial management, the patient was referred to cardiology department for further investigations. He revealed a typical stable angina from two months. The EKG showed Antero-septal necrosis (QS from V1 to V3).

Trans-thoracic echocardiogram exam (apical four-chamber view) demonstrated a giant thrombus attached at the left ventricular apex, an impaired left ventricular ejection fraction with an antero-septal akinesis. Supra Aortic Doppler showed no stenosis. Coronary angiography revealed right coronary artery occlusion and a left coronary artery dissection. Patient was referred for a coronary artery bypass graft surgery. The postoperative course was uneventful and the patient was discharged few days later.

Discussion

Central retinal artery occlusion is a rare but one of the ophthalmological emergency with worse prognosis that causes definite loss of vision within few hours of installation [1]. The incidence is estimated to be 1 in 100,000 people and accounts for 1 in 10,000 ophthalmological outpatient visits [2]. Assimilated to the ocular analogue of cerebral stroke, it results on impaired functional capacity and quality of life. Central retinal artery occlusion signifies end-organ ischemia and has the same risk factors that in turn place an individual at risk of future cerebral stroke and ischemic heart disease. Blood supply to the retina originates from the ophthalmic artery.

Typical funduscopic findings of a pale retina with a cherry red macula result from obstruction of blood flow to the retina from the retinal artery, causing pallor, and continued supply of blood to the choroid from the ciliary artery, resulting in a bright red coloration at the thinnest part of the retina. These findings do not develop until an hour or more after embolism, and they resolve within days of the acute event. By this time, visual loss is permanent and primary optic atrophy has developed. In those with a cilioretinal artery supplying the macula, a cherry red spot is not observed.

There is currently no guideline-endorsed evidence for treatment. Therapy options include sublingual isosorbide dinitrate, systemic

pentoxifylline or inhalation of a carbogen, hyperbaric oxygen, ocular massage, globe compression, intravenous acetazolamide and mannitol, anterior chamber paracentesis, and methylprednisolone with no superiority when compared to placebo [3]. There has been recent interest in the use of tissue plasminogen activator (tPA) on the treatment of acute central retinal artery occlusion [4].

Causes of central retinal artery occlusion vary depending on the age and the risk factors of the patient. An embolism, atherosclerotic changes, inflammatory endarteritis, angiospasm, or hydrostatic arterial occlusion may occlude the retinal artery. The mechanism of obstruction may be obvious from comorbid systemic disease or physical findings. Atrial fibrillation and ipsilateral carotid stenosis are more commonly associated with prolonged visual disturbances. Varma and al suggested a Vascular Workup for Patients with central retinal artery occlusion (**Table 1**) [1]. 64% of patients suffering a CRAO had at least one new undiagnosed vascular risk factor, the most common being hyperlipidaemia (36%), followed by hypertension (27%) and diabetes (12%) [5]. In addition, 27% of patients had an ipsilateral carotid stenosis of >50%. The result is analogous to another study, which found that 31% of patients had ipsilateral carotid stenosis of >50 and 71% had atherosclerotic plaques. In all, 52% had an abnormal echocardiogram, suggesting a cardioembolic source [6].

In our case, the etiology was an Embolus from the heart is the most common cause of CRAO in patients younger than 40 years. Emboli to the retinal circulation may originate at any point in the proximal circulation from the heart to the ophthalmic artery [7].

Conclusion

Ischemic cardiomyopathy is not rare and has the same risk factors that causes systemic vascular disease. Investigating by a cardiovascular examination should be one of the major steps in the Workup for Patients with central retinal artery occlusion.

Competing interests

The authors declare no competing interests.

Authors' contributions

IZ analyzed and interpreted the patient data regarding the cardiac mass and performed the final review of the manuscript. JZ helped to conduct the review of the literature and made a major contribution to the writing of the manuscript. JB and IZ prescribed treatment and follow up the patient. MC analyzed and interpreted the patient imaging data. JZ translated and reviewed the manuscript. All authors read and approved the final manuscript.

Acknowledgements

We thank the colleagues and the personnel of Habib Thameur Hospital at who have been of invaluable assistance.

Table and figures

Table 1: Suggested vascular workup for patients with central retinal artery occlusion [1]

Figure 1: Colour fundus photograph of the left eye showing acute CRAO with cherry-red spot and cattle trucking of the arterioles

Figure 2: Fundus fluoresce in angiography. (A) 25seconds from injection: no distal opacification; (B) 180seconds from injection: multiple intra-arterial emboli with delayed opacification of distal branches

References

1. Varma DD et al. A review of central retinal artery occlusion: clinical presentation and management. *Eye (Lond)*. 2013; 27(6):688-97. [PubMed](#) | [Google Scholar](#)
2. Rumelt S, Dorenboim Y, Rehany U. Aggressive systematic treatment for central retinal artery occlusion. *Am J Ophthalmol*. 1999;128(6):733-8. [PubMed](#) | [Google Scholar](#)
3. Fraser SG, Adams W. Interventions for acute non-arteritic central retinal artery occlusion. *Cochrane Database Syst Rev*. 2009 Jan 21;(1):CD001989. [PubMed](#) | [Google Scholar](#)
4. Feltgen N et al. Multicenter study of the European Assessment Group for Lysis in the Eye (EAGLE) for the treatment of central retinal artery occlusion: design issues and implications: EAGLE Study report no 1. *Graefes Arch Clin Exp Ophthalmol*. 2006;244(8):950-6. [PubMed](#) | [Google Scholar](#)
5. Rudkin AK, Lee AW, Chen CS. Vascular risk factors for central retinal artery occlusion. *Eye (Lond)*. 2010; 24(4):678-81. [PubMed](#) | [Google Scholar](#)
6. Hayreh SS. Acute retinal arterial occlusive disorders. *Prog Retin Eye Res*. 2011;30(5):359-94. [PubMed](#) | [Google Scholar](#)
7. Caglar C, Caglar Z, Gul A. The central retinal artery occlusion in the right eye followed by a branch retinal artery occlusion in the left eye four days later. *Indian J Ophthalmol*. 2013;61(11):667-9. [PubMed](#) | [Google Scholar](#)

Table 1: suggested vascular workup for patients with central retinal artery occlusion [1]	
Common vascular risk factors (all patients)	Blood pressure
	Fasting lipids and lipid profile
	Fasting blood sugar
Exclusion of arteritic CRAO Investigations for embolic sources	ESR, CRP, Platelet count
	Duplex carotid ultrasound
	Echocardiogram
Younger patients (<50 years old) with no vascular risk factors	Thrombophilia screen (protein C and S, factor V Leiden, antiphospholipid antibody), vasculitic screen (ANA, ENA, ANCA, ACE)
Erythrocyte sedimentation rate (ESR), C-reactive protein (CRP)	

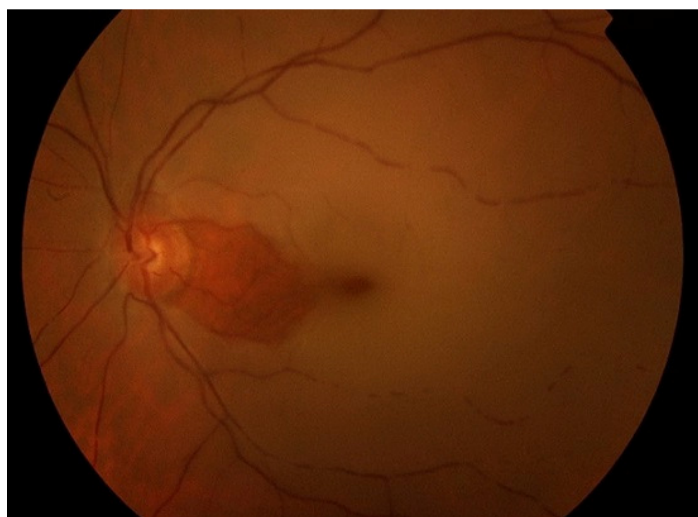

Figure 1: Colour fundus photograph of the left eye showing acute CRAO with cherry-red spot and cattle trucking of the arterioles

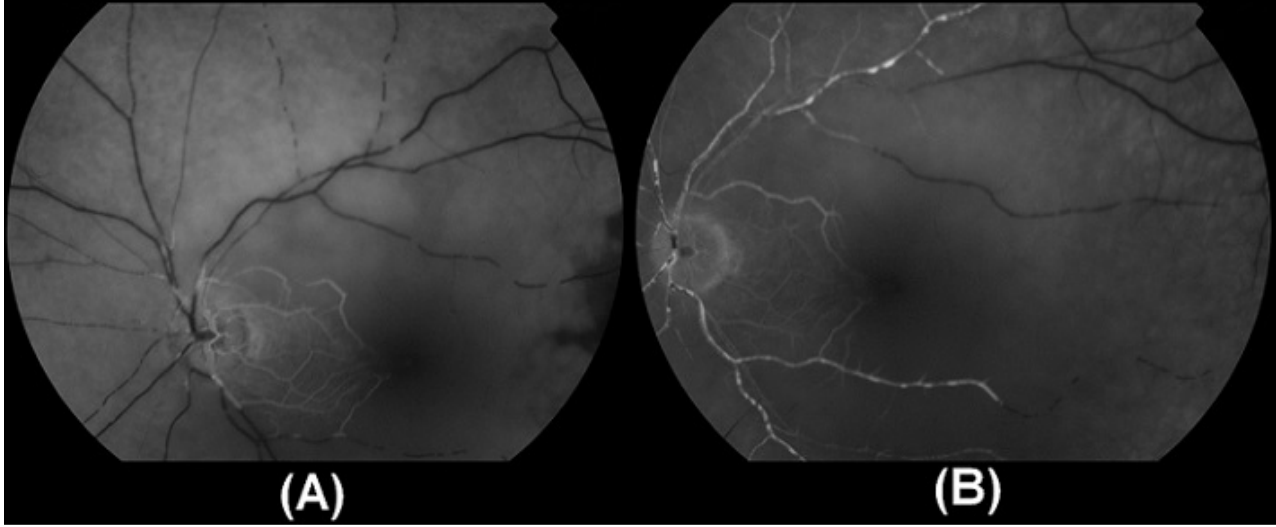


Figure 2: Fundus fluorescein angiography. (A) 25seconds from injection: no distal opacification; (B) 180seconds from injection: multiple intra-arterial emboli with delayed opacification of distal branches