

## Images in medicine

### Giant adenoid cystic carcinoma of the sinonasal cavity

Mohamed Mliha Touati<sup>1, &</sup>, Haddou Ammar<sup>1</sup>

<sup>1</sup>ENT Department, Military Hospital Avicenna, Marrakech, Morocco

<sup>&</sup>Corresponding author: Mohamed Mliha Touati , ENT Department, Military Hospital Avicenna, Marrakech, Morocco

Key words: Sinonasal cavity, adenoid cystic carcinoma, ethmoidomaxillonasal tumor

Received: 26/11/2014 - Accepted: 01/12/2014 - Published: 02/06/2015

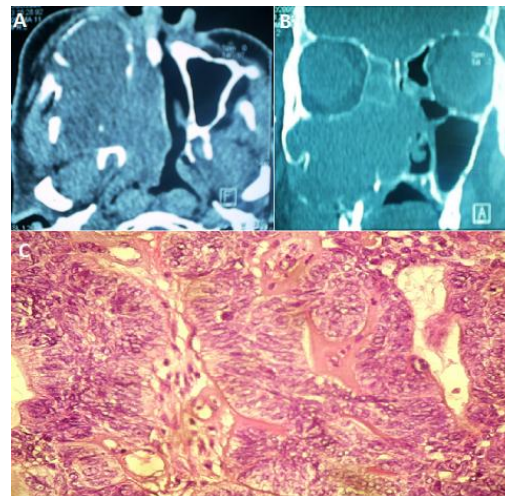
**Pan African Medical Journal. 2015; 21:82 doi:10.11604/pamj.2015.21.82.5833**

This article is available online at: <http://www.panafrican-med-journal.com/content/article/21/82/full/>

© Mohamed Mliha Touati et al. The Pan African Medical Journal - ISSN 1937-8688. This is an Open Access article distributed under the terms of the Creative Commons Attribution License (<http://creativecommons.org/licenses/by/2.0>), which permits unrestricted use, distribution, and reproduction in any medium, provided the original work is properly cited.

#### Image in medicine

Adenoid cystic carcinomas, formerly known cylindromas, were originally described by Foote and Frozell 1953. These are epithelial malignancies that develop at the expense of salivary glands, other rare localizations have been described in particular in the oral cavity, the sinonasal tract, lacrimal glands or nasopharynx. Clinical and radiological signs are not specific, and are common to all sinonasal tumors, including squamous cell carcinomas and adenocarcinomas. The adequate treatment is surgery, postoperative radiation therapy improves long-term prognosis. These tumors are characterized by aggressiveness and a high incidence of local recurrence and distance metastasis regardless of therapeutic modalities used. We report a case of a 70 year old patient, hospitalized for exploration of a large sinonasal tumors, CT Scann of the face and sinonasal cavities disclosed a large right ethmoidomaxillonasal tumor, with tissue density with and contrast enhancement, lysing all the walls of the maxillary sinus, septum and the horizontal branch of the mandible. With extension to the infratemporal fossa, the orbital floor, the contralateral nasal cavity, the floor of the nasal cavity and nasopharynx. A nasal biopsy concluded to an adenoid cystic carcinoma, The staging revealed no distant metastases, the tumor was classified T4NoMo. The patient refused any surgery, he was referred for palliative radiotherapy, it was lost sight of.



**Figure 1:** (A): computed tomography of the sinonasal area, axial section with contrast medium injection, showing a tumor process the right maxillary sinus with extension to the nasal cavity and the infratemporal fossa and bone erosion, (B) : computed tomography of the sinonasal area, coronal section showing a large ethmoidomaxillary tumor process extended to the nasal cavity with lysis of intersinus nasal wall and nasal septum, (C) : adenoid cystic carcinoma: cribriform lobules composed of somewhat irregular cells scattered in a fibrohyaline stroma. HE x100