

Images in medicine

An unusual appearance of giant Meckel's diverticulum

Mbarek Yaka^{1,&}

¹Department of Surgery, Military Hospital Med Rabat, Morocco

[&]Corresponding author: Mbarek Yaka , Depatement of Surgery, Military Hospital Med Rabat, Morocco

Key words: Giant Meckel 's diverticulum, diverticulitis, unusual appearance

Received: 16/06/2015 - Accepted: 25/06/2015 - Published: 03/07/2015

Pan African Medical Journal. 2015; 21:177 doi:10.11604/pamj.2015.21.177.7286

This article is available online at: <http://www.panafrican-med-journal.com/content/article/21/177/full/>

© Mbarek Yaka et al. The Pan African Medical Journal - ISSN 1937-8688. This is an Open Access article distributed under the terms of the Creative Commons Attribution License (<http://creativecommons.org/licenses/by/2.0>), which permits unrestricted use, distribution, and reproduction in any medium, provided the original work is properly cited.

Image in medicine

Meckel's diverticulum (MD) results from incomplete involution of the proximal portion of the vitelline duct. Although MD is the most commonly diagnosed congenital gastrointestinal anomaly, it is estimated to affect only 2% of the population worldwide. Most cases are asymptomatic, and diagnosis is often made following investigation of unexplained gastrointestinal bleeding, perforation, inflammation or obstruction that prompt clinic presentation. While MD range in size from 1-10 cm, cases of giant MD (≥ 5 cm) are relatively rare and associated with more severe forms of the complications. Herein, we report a 43-year-old male patient presented at the Emergency Department with a complaint of abdominal pain, associated with fever (38,5C), nausea and anorexia. The clinical examination revealed pain in the right lower quadrant, as well as abdominal guarding and rebound tenderness. The leucocyte count was elevated at $18 \times 10^9/L$. Plain abdominal x-ray depicted multiple air-fluid levels. An abdominal and pelvic CT scan revealed a fluid-filled structure in the pelvis adjacent to the distal small bowel. The surgical method of exploration can be either by laparoscopy or through an open incision. Exploratory laparotomy was performed and revealed oedema throughout the entire small bowel, dilation of small bowel segments, and a giant Meckel's

diverticulum (10 cm long) with mushroom appearance on the antimesenteric border of the small bowel at 70 cm proximal to the ileocaecal valve . Resection of the small bowel was performed with a linear stapler and an ileoileal anastomosis was generated using a 80 mm endo-GIA stapler. Patient was discharged on post-operative day 4 without any complications. Histopathologic examination indicated Meckel's diverticulitis without gastric or pancreatic metaplasia.

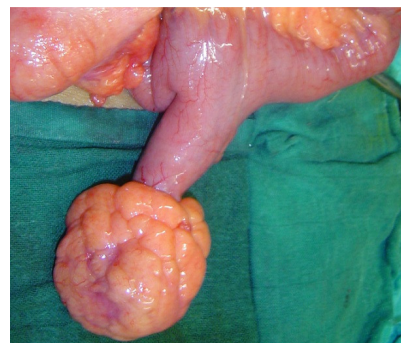


Figure 1: giant inflamed Meckel's diverticulum with mushroom appearance