

Case report

Hydatid cyst of the pericardium: a case report

Abdelilah Mouhsine^{1,§}, Ahmed Belkouch², El Mehdi Athmane¹, Redouane Roukhssi¹, Abdelghani EL Fikri¹, Lahcen Belyamani², Mbarek Mahfoudi¹

¹Department of Radiology, Avicenna Military Hospital, Faculty of Medicine and Pharmacy, Marrakech, Morocco, ²Emergency Department, Mohamed V Military Hospital of Instruction, Faculty of Medicine and Pharmacy, Rabat, Morocco

[§]Corresponding author: Abdelilah Mouhsine, Department of Radiology, Avicenna Military Hospital, Faculty of Medicine and Pharmacy, Marrakech, Morocco

Key words: CT scan, echocardiography, hydatid cyst, MRI, pericardium

Received: 03/10/2014 - Accepted: 06/11/2014 - Published: 27/11/2014

Abstract

Pericardial hydatid cysts are a rare condition; its clinical presentation is variable. It can reveal straightaway at the stage of life threatening complications. We report the case of a 17 years old female Arab patient, who complained of a sudden onset dyspnea, clinical examination was poor; the diagnosis was suspected by echocardiography and confirmed by the CT scan and hydatid serology. Furthermore, no other location was noted. Surgical treatment was proposed. The modern cross-sectional imaging especially CT scan and MRI revolutionized the diagnosis of this rare hydatid location.

Pan African Medical Journal. 2014; 19:330 doi:10.11604/pamj.2014.19.330.5542

This article is available online at: <http://www.panafrican-med-journal.com/content/article/19/330/full/>

© Abdelilah Mouhsine et al. The Pan African Medical Journal - ISSN 1937-8688. This is an Open Access article distributed under the terms of the Creative Commons Attribution License (<http://creativecommons.org/licenses/by/2.0>), which permits unrestricted use, distribution, and reproduction in any medium, provided the original work is properly cited.

Introduction

Hydatidosis rages at the endemic state in some regions of the world, it is a major public health problem; it is due to the human's accidental infestation by the larval form of the parasite [1]. The hydatid cyst of the pericardium is a rare localization; it is a serious condition because it exposes to life threatening complications.

Patient and observation

A 17 years old young woman was admitted to the emergency department for the management of a sudden onset dyspnea. She had no history. Clinical examination revealed a dyspneic but conscious patient, with no fever. Respiratory rate was 22 cycles/min, SpO₂=92% in the open air, heart rate=114 beats/min, blood pressure=144/95. She received supplemental oxygen at 4 l/min via nasal cannula, SpO₂ improved and increased to 98%. A biological assessment was requested and revealed anemia to 10g/dl of hemoglobin. The remaining biological record was normal. Chest radiograph showed discrete cardiomegaly, cardio thoracic index was at 0.55. No other pleural or pericardial abnormalities were noted. Transthoracic echocardiography showed a fluid compartmentalized cystic anechoic lesion, homogeneous, compressing the right cavities of the heart. Chest CT scan (**Figure 1, Figure 2, Figure 3, Figure 4**) showed discrete cardiomegaly with pericardial lesion facing the right cavities especially the right ventricle, this lesion is relatively toned, fluid density, encapsulated, seat of few banded membrane structures. This lesion measures 8 cm (longitudinal axis), 7 cm (transverse axis), and compresses the next ventricular myocardium, it suggests first of all pericardial hydatid cyst. Abdominal ultra sound was normal. There after the patient was admitted to cardiology; hydatid serology was performed and was positive. Surgical treatment was proposed but the patient refused it.

Discussion

Hydatidosis is a problem of public health in some regions of the world where it rages at the endemic state, as north-Africa, some regions of the Mediterranean Sea and in the Middle East [1]. It is a parasitosis due to the infestation by the larva of the tenia echinococcus granulosis. Humans are accidental hosts of this

parasite after ingestion of the parasite eggs or scolex. These eggs cross the small intestines after having lost their envelopes, join the portal circulation and then reach the liver. Hydatid cyst affects in most cases the liver (59-75%) the lungs (27%) kidneys (3%) bones (1-4%) the central nervous system (1-2%).The heart, spleen, pancreas, muscles, adrenal glands, the parotid gland, thyroid and prostate are exceptional locations of this parasite [2]. Cardiac location represents 0.5 to 2% of all hydatid cyst localizations [3]. It is isolated in 2/3 of time. The intracardiac location varies: left ventricle is involved in 60% of cases, interventricular septum in 9-20%, right ventricle and right atrium in 4-17%. Pericardial hydatid cyst has been very little reported in the literature, it is a serious condition because it exposes to severe complications [4]. The clinical manifestations of pericardial hydatid cyst depend of its seat, size and number of cysts [2, 5].The symptoms may be non-specific as chest pain, palpitation, effort dyspnea as for our patient, sometimes the discovery is fortuitous; it can also manifest as complication: intrapericardial rupture causing tamponade, cardiac arrest. Chest radiography is not contributive to the diagnosis, it may show cardiomegaly with uni or bilobed deformation of the cardiac silhouette, arcuate calcifications, and can be associated with pulmonary localization. In our case it revealed a discrete isolated cardiomegaly.

Transthoracic or transesophageal echocardiography is an indispensable and efficient examination, it can analyze the cyst characteristics, uni or multi locular, its topography, appearance and its relationship with the heart chambers. It may reveal an associated pericardial or pleural effusion. Some aspects are strongly suggestive of hydatid cyst as a detached layer or a multivesicular appearance [6]. For our patiente chocardiography revealed the lesion but it was the CT scan that permitted to specify its characteristics. Indeed CT scan better specifies its relationship with adjacent vital structures, it is usually a hypodense Uni-or multicelled lesion, not enhanced after injection of contrast material unless infection; it also allows to search other local and loco regional lesions. Abdominal ultrasound is useful to search for an associated hepatic localization. MRI is indicated in case of doubtful diagnosis or in case of divergence between the echocardiographic and CT scan findings. It permits a better characterization of the lesion and precise better the anatomical relationships. The hydatid cyst presents then as a liquid signal lesion in low signal T1, and high signal T2, daughter cysts are revealed in low signal T1 and in low or T2 high signal according to the presence or not of scolices achieving the aspect of the "cyst in the cyst". The detached layers within the cyst are responsible of a

linear or banded low signal inside the cyst giving the aspect of the "Rim sign". Hydatid serology is not very useful to the diagnosis. It is only positive in half cases. Immuno-electrophoresis is more specific. The pathological examination confirms the diagnosis. The treatment is surgical [7, 8], although some studies have reported cases treated using benzimidazoles (albendazole, mebendazole) [9].

Conclusion

The pericardial location of hydatid cyst is rare, its clinical expression is polymorphic and can expose to life threatening complications. The cross-sectional imaging is the gold standard for the diagnosis especially CT and MRI. Serology may be helpful. Treatment is primarily surgical.

Competing interests

The authors declare that they have no competing interest.

Authors' contributions

All authors have read and agreed to the final version of this manuscript and have equally contributed to its content and to the management of the case.

Figures

Figure 1: thoracic helical CT scan in axial acquisition after injection of contrast material showing a pericardial cystic lesion next to the right cavities especially the right ventricle, a detached layer is seen within the lesion, which compresses the ventricular myocardium

Figure 2: reconstructed coronal CT scan showing the same image of the pericardial cystic lesion next to the right ventricle

Figure 3: sagittal CT scan reconstructions after injection of contrast material in mediastinal view showing the same lesion next to right cavities with a detached layer within it

Figure 4: pericardial lesion next to right cavities

References

1. Blanton R. Echinococcosis. In: Behrman RE, Kliegman RM, Jenson HB, editors. Nelson Textbook of Pediatrics 17 Philadelphia: WB Saunders Company. 2004; 1173-4. **PubMed | Google Scholar**
2. Pedrosa I, Saíz A, Arrazola J, Ferreirós J, Pedrosa CS. Hydatid Disease: Radiologic and Pathologic Features and Complications. Radio Graphics. 1 mai 2000; 20(3):795-817. **PubMed | Google Scholar**
3. Dighiero J, Canabal EJ, Aguirre CV, Hazan J, Horjales JO. Echinococcus disease of the heart. Circulation. janv 1958;17(1):127-32. **PubMed | Google Scholar**
4. Noah MS, el Din Hawas N, Joharjy I, Abdel-Hafez M. Primary cardiac echinococcosis: report of two cases with review of the literature. Ann Trop Med Parasitol. Févr1988; 82(1):67-73. **PubMed | Google Scholar**
5. De Martini M, Nador F, Binda A, Arpesani A, Odero A, Lotto A. Myocardial hydatid cyst ruptured into the pericardium: cross-sectional echocardiographic study and surgical treatment. Eur Heart J. juill 1988; 9(7):819-24. **PubMed | Google Scholar**
6. Kudaiberdiev T, Djoshibaev S, Yankovskaya L, Djumanazarov A. Multiple hydatid cysts of epicardium and pericardium. Int J Cardiol. déc 2001; 81(2-3):265-7. **PubMed | Google Scholar**
7. Thameur H, Abdelmoula S, Chenik S, Bey M, Ziadi M, Mestiri T, et al. Cardiopericardial hydatid cysts. World J Surg. janv 2001; 25(1):58-67. **PubMed | Google Scholar**
8. Birincioglu CL, Bardakci H, Küçüker SA, Ulus AT, Arda K, Yamak B, et al. A clinical dilemma: cardiac and pericardiac echinococcosis. Ann Thorac Surg. oct 1999; 68(4):1290-4. **PubMed | Google Scholar**
9. Goksel S, Kural T, Ergin A, Engel A, Özer C, Küçük E. Hydatid cyst of the interventricular septum: diagnosis by cross-sectional echocardiography and computed tomography, treatment with mebendazole. Jpn Heart J. 1991; 32:741-4. **PubMed | Google Scholar**

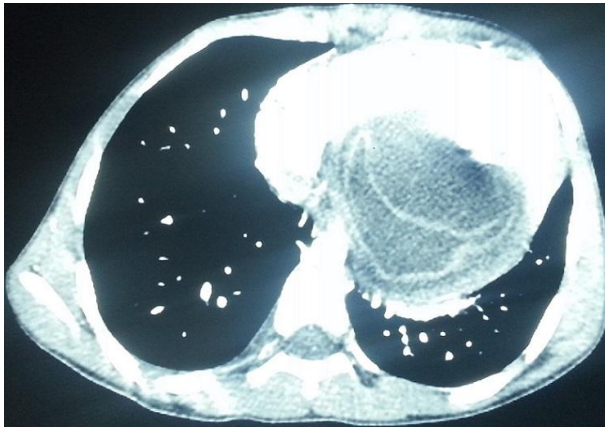


Figure 1: thoracic helical CT scan in axial acquisition after injection of contrast material showing a pericardial cystic lesion next to right cavities especially the right ventricle, a detached layer is seen within the lesion, which compresses the ventricular myocardium

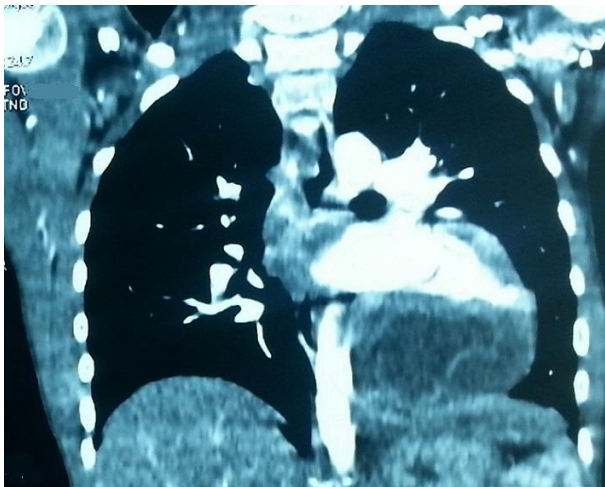

Figure 2: reconstructed coronal CT scan showing the same image of the pericardial cystic lesion next to the right ventricle

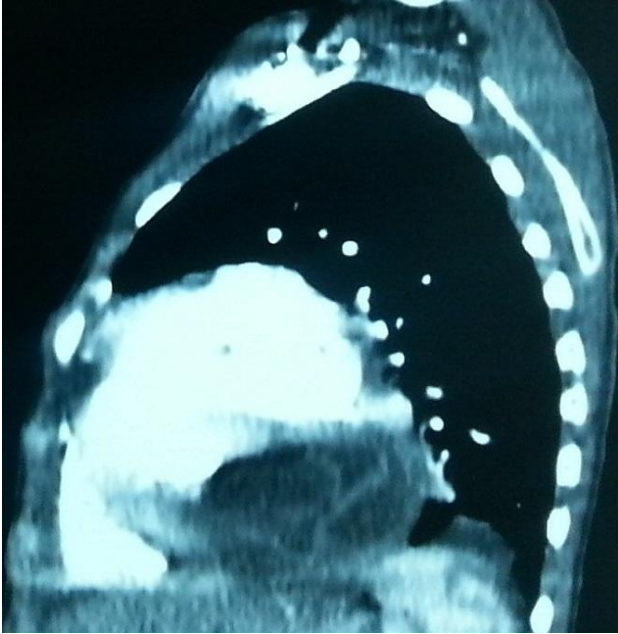

Figure 3: sagittal CT scan reconstructions after injection of contrast material in mediastinal view showing the same lesion next to right cavities with a detached layer within it

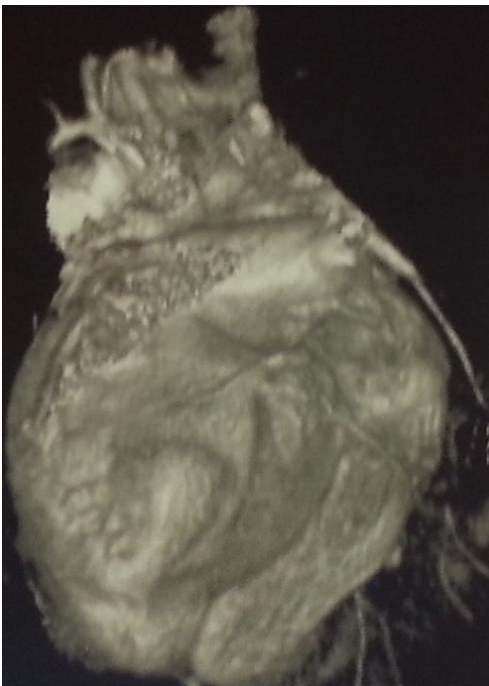


Figure 4: pericardial lesion next to right cavities