

## Images in medicine

### A Christmas tree cataract

Fadoua Zahir<sup>1, &</sup>, Hicham Tahri<sup>1</sup>

<sup>1</sup>Ophthalmology Service, CHU Hassan II, Fez, Morocco

<sup>&</sup>Corresponding author: Fadoua Zahir, Ophthalmology Service, CHU Hassan II, Fez, Morocco

Key words: Christmas tree, cataract, anterior nucleus

Received: 09/06/2014 - Accepted: 10/08/2014 - Published: 25/08/2014

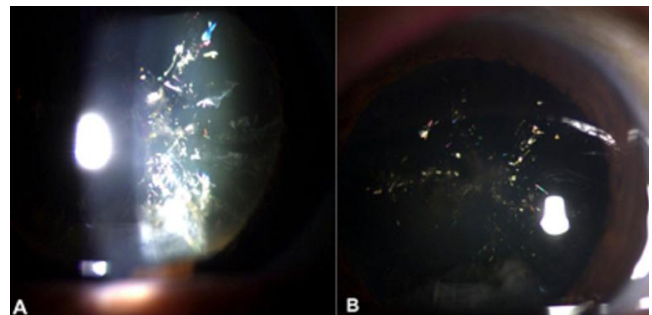
**Pan African Medical Journal. 2014; 18:332 doi:10.11604/pamj.2014.18.332.4780**

This article is available online at: <http://www.panafrican-med-journal.com/content/article/18/332/full/>

© Fadoua Zahir et al. The Pan African Medical Journal - ISSN 1937-8688. This is an Open Access article distributed under the terms of the Creative Commons Attribution License (<http://creativecommons.org/licenses/by/2.0>), which permits unrestricted use, distribution, and reproduction in any medium, provided the original work is properly cited.

### Image in medicine

A 70-year-old man referred for cataract surgery, had on examination a palette of colored needle-shaped opacities in the cortex and anterior nucleus of the lens, consistent with unilateral Christmas tree cataract. This type of cataract result from the accelerated breakdown of membrane associated proteins. The peptides and amino-acids accumulate in the lumen of the reticular meshwork, and cystine is concentrated beyond the level of crystallization, giving rise to growing crystals.



**Figure 1:** palette of colored needle-shaped opacities in the cortex and anterior nucleus of the lens (A and B)