

Images in medicine

Acute traumatic maculopathy

Omar Lezrek^{1,*}, Mounir Lezrek¹

¹Mohammed V University Souissi, Faculty of Medicine, Department A of Ophthalmology, Rabat, Morocco

*Corresponding author: Omar Lezrek, Mohammed V University Souissi, Faculty of Medicine, Department A of Ophthalmology, Rabat, Morocco

Key words: Maculopathy, trauma, blurry vision, Funduscopy, optical coherence tomography

Received: 14/05/2014 - Accepted: 06/06/2014 - Published: 11/06/2014

Pan African Medical Journal. 2014; 18:133 doi:10.11604/pamj.2014.18.133.4595

This article is available online at: <http://www.panafrican-med-journal.com/content/article/18/133/full/>

© Omar Lezrek et al. The Pan African Medical Journal - ISSN 1937-8688. This is an Open Access article distributed under the terms of the Creative Commons Attribution License (<http://creativecommons.org/licenses/by/2.0>), which permits unrestricted use, distribution, and reproduction in any medium, provided the original work is properly cited.

Image in medicine

A 14-year old child presented to the emergency department (ED), complaining of blurry vision one hour after he was victim of a blunt trauma of his right eye. Initially, visual acuity was Counting Fingers at 2m and 20/20 in the left eye, Slit lamp examination was normal; Funduscopy of the right eye revealed gray-white discoloration of macula and lower retina in posterior pole (A); Optical coherence tomography showed an increase in reflectivity of the inner and outer segment junction (B); 1 week later, the visual acuity improved to 20/25 in the right eye without any treatment.

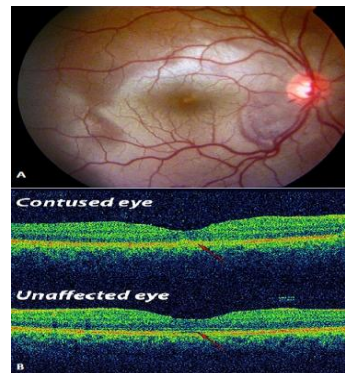


Figure 1: A) Fundus photography; B) difference between macular OCT in contused eye and the healthy eye