

## Images in medicine

### First presentation of guttate psoriasis triggered by acute tonsillitis

Theocharis Koufakis<sup>1,§</sup>, Ioannis Gabranis<sup>1</sup>

<sup>1</sup>Department of Internal Medicine, General Hospital of Larissa, Larissa, Greece

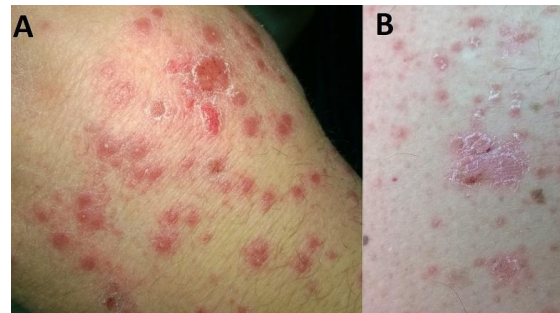
<sup>§</sup>Corresponding author: Theocharis Koufakis, Department of Internal Medicine, General Hospital of Larissa, Larissa, Greece

Key words: Guttate psoriasis, tonsillitis

Received: 19/03/2014 - Accepted: 11/04/2014 - Published: 14/04/2014

#### Image in medicine

We present a case of a 33 years old man who presented to the Emergency Department of our Hospital with small, red, drop-like lesions located at his arms, legs, torso and back. He had no history of any dermatological disease, but he had a positive maternal family history for plaque psoriasis. The patient had recently recovered from acute tonsillitis after receiving amoxicillin - clavulanic acid therapy. The diagnosis of guttate psoriasis was clinically established, based on the typical presentation and the history of recent upper respiratory infection. He was treated with a combination of oral and topical corticosteroids and he was advised to have frequent follow-up visits to our Dermatology Department. Guttate psoriasis (also known as "Eruptive psoriasis") is more common in young adults and often follows a bacterial or viral infection, but it has also been associated with drugs, stress, skin injury and other trigger factors.



**Figure 1:** Small, red, drop-like lesions of Guttate psoriasis located at the hand (A) and the arm (B) of the patient

**Pan African Medical Journal. 2014; 17:273 doi:10.11604/pamj.2014.17.273.421**

This article is available online at: <http://www.panafrican-med-journal.com/content/article/17/273/full/>

© Theocharis Koufakis et al. The Pan African Medical Journal - ISSN 1937-8688. This is an Open Access article distributed under the terms of the Creative Commons Attribution License (<http://creativecommons.org/licenses/by/2.0>), which permits unrestricted use, distribution, and reproduction in any medium, provided the original work is properly cited.