

Images in medicine

Traumatic peroneal nerve injury in an adolescent with asymptomatic tibial osteochondroma

Ali Akhaddar^{1,2,&}, Mustapha Boussouga^{2,3}

¹Department of Neurosurgery, Avicenne Military Hospital, Marrakech, Morocco, ²University of Mohammed V Souissi, Rabat, Morocco, ³Department of Orthopedic Surgery, Mohammed V Military Teaching Hospital, Rabat, Morocco

[&]Corresponding author: Ali Akhaddar, Department of Neurosurgery, Avicenne Military Hospital, Marrakech, Morocco

Key words: Nerve injury, osteochondroma, tibia, adolescent

Received: 09/02/2014 - Accepted: 18/02/2014 - Published: 28/02/2014

Pan African Medical Journal. 2014; 17:145 doi:10.11604/pamj.2014.17.145.3997

This article is available online at: <http://www.panafrican-med-journal.com/content/article/17/145/full/>

© Ali Akhaddar et al. The Pan African Medical Journal - ISSN 1937-8688. This is an Open Access article distributed under the terms of the Creative Commons Attribution License (<http://creativecommons.org/licenses/by/2.0>), which permits unrestricted use, distribution, and reproduction in any medium, provided the original work is properly cited.

Image in medicine

A 15-year-old adolescent, previously healthy, presented with right peroneal nerve palsy sustained after a direct closed knee injury in a soccer game. The physical examination revealed a marked weakness to dorsiflexion of the right ankle and toes without sensory loss. A bony mass was noted in the right postero-lateral area of the knee. Plain radiographs and a computed tomography-scan of the knee showed a large osteophytic mass in the proximal metaphyse of the right tibia with an important mass effect on the fibular head which is deformed (A-D). Electrophysiological studies confirmed denervation of the muscles supplied by the right peroneal nerve. The patient underwent surgical decompression of the nerve after resection of the osseous mass. Postoperatively, there was a progressive improvement of the nerve function. The patient was referred for physiotherapy care. Histological features were consistent with benign osteochondroma. Osteochondromas (exostosis) frequently develop around the knee in the distal femur and the proximal tibia and fibula. These osteocartilaginous tumors are usually asymptomatic, but can occasionally impinge on the surrounding nerves and vessels and cause various clinical manifestations. Tibial osteochondroma compressing both the fibular head and the peroneal nerve is rarely seen especially following a direct injury.

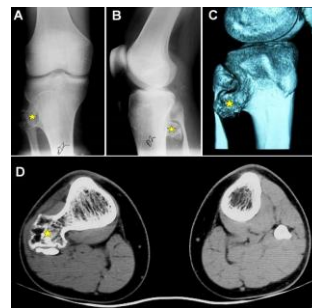


Figure 1: Right knee: Antero-posterior (A) and lateral (B) plain radiographs. 3-D CT-scan bony reconstruction (C) with axial CT-scan of both proximal tibias and fibulas (C-D) showing a large osteophytic bony lesion (star) in the proximal metaphyse of the right tibia with an important mass effect on the fibular head which is deformed (A-D)