

# Images in medicine

## Eales disease: no typical clinical presentation

Belmokhtar Adil<sup>1,\*</sup>, Daoudi Rajaa<sup>1</sup>

<sup>1</sup>University Mohamed V Souissi, Hôpital des Spécialités, Ophtalmologie A Department, Morocco

<sup>\*</sup>Corresponding author: Belmokhtar Adil, University Mohamed V Souissi, Hôpital des Spécialités, Ophtalmologie A Department, Morocco

Key words: Eales disease, retinal phlebitis, visual acuity

Received: 13/02/2014 - Accepted: 17/02/2014 - Published: 26/02/2014

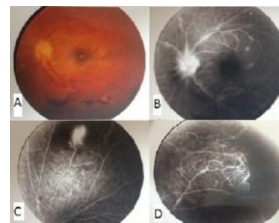
**Pan African Medical Journal. 2014; 17:136 doi:10.11604/pamj.2014.17.136.4019**

This article is available online at: <http://www.panafrican-med-journal.com/content/article/17/136/full/>

© Belmokhtar Adil et al. The Pan African Medical Journal - ISSN 1937-8688. This is an Open Access article distributed under the terms of the Creative Commons Attribution License (<http://creativecommons.org/licenses/by/2.0>), which permits unrestricted use, distribution, and reproduction in any medium, provided the original work is properly cited.

### Image in medicine

Eales disease is clinically manifested by retinal phlebitis, the onset of ischemia and retinal vessels neo area is often revealed by vitreous hemorrhage. Its etiology remains unknown. The management of this disease depends on the clinical presentation. Our patient was 27 years old, consults for a progressive loss of visual acuity unilateral in her left eye. On fundus exam at the emergency department, we found a vitreous hemorrhage, retinal hemorrhage, periphlebitis and retinal periphery ischemia (A). Laboratory tests were negative for potentially occlusive vasculopathy. Angiogram shows retinal neovascularization (B) and peripheral ischemic lesions (C, D). The patients received treatment with corticosteroids supplemented by laser photocoagulation. Improved visual acuity was obtained.



**Figure 1 :** A) vitreous hemorrhage, retinal hemorrhage, periphlebitis and retinal periphery ischemia ; (B, C, D): shows retinal neovascularization and peripheral ischemic lesions